

# Are fissure sealants still relevant as a caries preventive measure?

SADJ July 2016, Vol 71 no 6 p272 - p273

R Mulder

## INTRODUCTION

The groundwork for fissure sealants was completed in 1955 and led to the introduction in 1971 of the Nuva-Seal Fissure Sealant by L.D Caulk.<sup>1,2</sup> Since caries predominantly affects the pits and fissures of the teeth of children, these sealants have been shown to be a valuable preventive procedure.<sup>3</sup> FS are cost effective<sup>4</sup> and provide an ideal preventive measure for children who have restricted access to dental services.<sup>5</sup>

However the advent of dental lasers, caries detection systems, fluoride varnishes and novel adhesive systems may have displaced FS as a preventive measure of choice.

The aim of this investigation was to establish whether FS remain a relevant preventive measure for the anatomically vulnerable fissure system.

## METHODOLOGY

A sample of twenty extracted third molar teeth, which had been erupted and exposed to the oral environment, were selected after visual inspection had confirmed on each tooth the presence of a fissure system that was anatomically vulnerable and suitable for the placement of a FS. The fissure systems of both the control group (n=10) and the test group (n=10) were cleaned with a moist bristle brush to remove any pellicle or debris. Fissure sealants were placed on the teeth of the test group according to the manufacturer's instructions (Clinpro fissure sealant, 3M ESPE).

Thermocycling of the FS group and the control group (with no FS) was performed in a 2% methylene blue solution (MB) for 200 cycles with a dwell time of 75 seconds in 8°C and 50°C MB. This methodology was in accordance with the ISO guideline for "Polymer-based pit and fissure sealants ISO 6874(2005) E". The teeth were then sectioned in a bucco-lingual direction into slices of a thickness of 200µm. The sections were viewed under 20X stereomicroscope magnification.

## DISCUSSION

It has been common practice that anatomically vulnerable fissures receive a FS as a preventive procedure. But do FS still have a place in a modern dental practice when

## ACRONYMS

**FS:** Resin pit and fissure sealants  
**MB:** 2% methylene blue solution

dental lasers, caries detection systems, various fluoride varnishes and novel adhesive systems are available?

All the teeth in the control group (n=10) showed some degree of MB penetration into the porous enamel fissure surface (Figure A). Even fissures that appeared on visual inspection to have no decalcification had MB penetration into the fissure system. In some cases the penetration extended to the dentinal enamel junction, with clearly identifiable enamel prism destruction (Figure B).

The group of teeth that had received FS protection demonstrated that MB penetration into all the fissure systems had been prevented. It became clear that fissure systems, although decalcified and even with an area of debris at the base of the narrow fissure, received adequate protection with FS application against the penetration of the MB solution during thermocycling (Figure C).

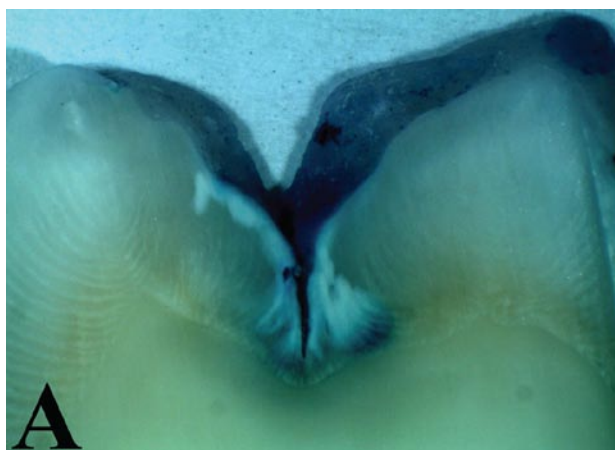## CLINICAL SIGNIFICANCE

Fissure sealants can therefore be considered an appropriate preventive procedure for the fissure system. The proven long term retention of up to 48 months of resin sealants in the fissure system of permanent molars provides the much needed resistance to fissure caries for children and adolescents.<sup>6,7</sup>

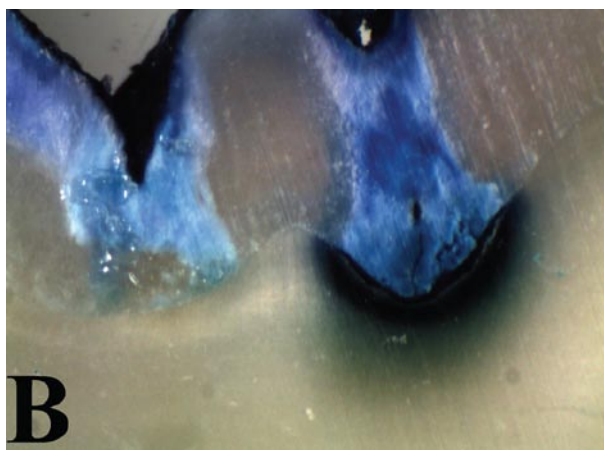
Fissure visualisation is essential and therefore a very fine explorer probe (FT10 probe) or pigtail probe should be used during the assessment of the fissure system to enhance the diagnostic skills of the clinician and to assist in the decision to place FS (Figure D).

Resin fissure sealants provide a simple yet efficacious preventive method and should continue to play an important role in the protection of anatomically vulnerable fissures of the teeth of young patients. The retained FS will prevent the progression of fissure demineralization to fissure caries. A recent systematic review indicated that irrespective of the FS material utilised (resin or glass ionomer) the preventive effect was similar and no material was identified as superior. FS as a preventive measure in sound occlusal fissures resulted in an approximate 70-80% reduction in the incidence of occlusal caries versus non treated occlusal fissures.<sup>8</sup> FS

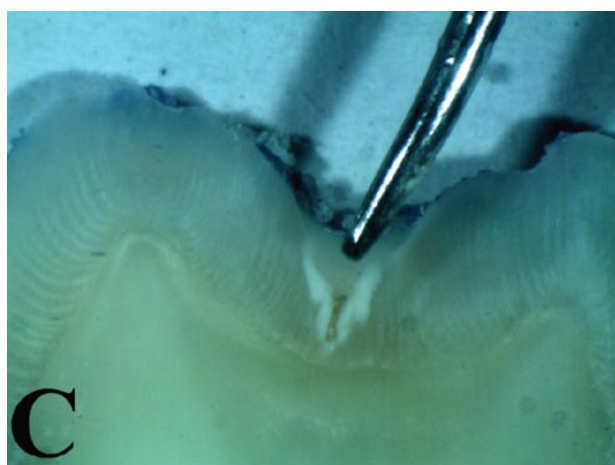
**Riaan Mulder:** BChD(UWC), MSc(Dent)(UWC). Lecturer, Faculty of Dentistry, University of the Western Cape. Department of Orthodontics and Paediatric Dentistry, Private Bag X1, Tygerberg 7505.  
 Tel: +27 21 937 3107, E-mail: rmulder@uwc.ac.za



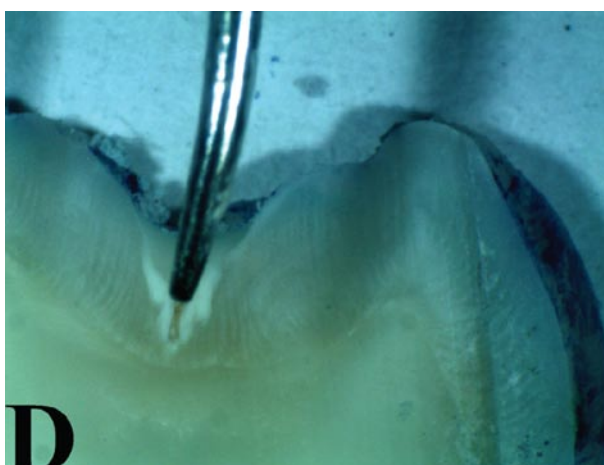
**Figure A:** MB staining of the fissure system of an anatomically vulnerable tooth with early enamel decalcification.



**Figure B:** The fissure system stained with MB of an anatomically vulnerable tooth with extensive enamel decalcification at the DEJ.



**Figure C:** Fissure system protected by sealant and showing no MB penetration, although debris was present in the narrow fissure, which could not be probed.



**Figure D:** Section demonstrating the importance of using a fine explorer or pig tail probe to carefully explore the fissure system.

were shown to be more effective in arresting non-cavitated pit and fissure caries compared with no treatment intervention or topical fluoride varnish application.<sup>8</sup> Dental lasers, caries detection systems, fluoride varnishes and novel adhesive systems all contribute to the endeavour to preserve the dentition, however, based on the available literature,<sup>8</sup> FS remain an important, and, as shown in this study, an effective, part of preventive dentistry.

**Conflict of interests:** None declared

#### References

1. Buonocore MG. A simple method of increasing the adhesion of acrylic filling materials to enamel surfaces. *J Dent Res* 1955;34:849-53.
2. Simonsen RJ. Pit and fissure sealant: review of the literature. *Paediatric Dentistry* 2002;24(5):398-414.
3. Macek MD, Beltrán-Aguilar ED, Lockwood SA, Malvitz DM. Updated comparison of the caries susceptibility of various morphological types of permanent teeth. *J Public Health Dent* 2003;63:174-82.
4. Weintraub JA. Pit and fissure sealants in high-caries-risk individuals. *J Dent Educ* 2001;65(10):1084-90.
5. Truman BI, Gooch BF, Sulemana I, Gift HC, Horowitz AM, Evans CA, *et al.* Reviews of evidence on interventions to prevent dental caries, oral and pharyngeal cancers, and sports-related craniofacial injuries. *Am J Prev Med* 2002;23(1):21S-54S.
6. Mickenautsch S, Yengopal V. Validity of sealant retention as surrogate for caries prevention: a systematic review. *PLoS ONE* 2013; 8:e77103.
7. Ahovuo-Saloranta A, Forss H, Walsh T, Hiiri A, Nordblad A,

Mäkelä M, Worthington HV. Sealants for preventing dental decay in the permanent teeth. *Cochrane Database of Systematic Reviews* 2013, 3(CD001830). DOI:10.1002/14651858.CD001830.pub4.

8. Wright, John T. *et al.* Sealants for preventing and arresting pit-and-fissure occlusal caries in primary and permanent molars. *The Journal of the American Dental Association* 2016;147(8): 631 - 45.e18. DOI: <http://dx.doi.org/10.1016/j.adaj.2016.06.003>