

# Determining an average distance from the external mandibular cortex to the inferior alveolar canal using cone beam computed tomography (CBCT) imaging: An aid to harvesting mandibular ramus autogenous grafts.

SADJ October 2016, Vol 71 no 9 p390 - p394

S Padayachee,<sup>1</sup> H Holmes,<sup>2</sup> ME Parker.<sup>3</sup>

## SUMMARY

**Objectives:** To provide average measurements relating the external mandibular cortex (EMC) to the inferior alveolar canal (IAC) using CBCT.

**Methods:** 100 CBCT images from UWC Dental hospital patient database were analysed using CBCT software (NewtomVGi Image works Corps) to produce coronal slices at four defined points along the IAC. Each point was measured from the IAC to the outer aspect of the mandibular buccal cortex and to the alveolar ridge crest (edentulous mandibles) or buccal cortical plate crest (dentate mandibles). The paired t-test was used to analyse right and left side measurements in order to test for differences in right and left side means.

**Results:** A mean width of 5.891mm ( $\pm 1.09$ ) from the IAC to the EMC in the horizontal plane and a mean height of 13.068mm ( $\pm 2.963$ ) from IAC to the alveolar crest or buccal cortical plate was demonstrated. Mean height was lower in edentulous mandibles (11.142mm in females; 13.490mm in males) than in dentate mandibles (12.916mm in females; 14.102 in males). There was no significant

difference in width values. Height values were greater in males (14.102mm) than in females (12.916mm), being marginally significant ( $p$ -value of 0.00948;  $p < 0.05$ ).

**Conclusions:** These measurements are clinically applicable when harvesting mandibular autogenous block grafts.

**Keywords:** CBCT; Autogenous ramus grafts, inferior alveolar nerve

Autogenous grafting in combination with the placement of dental implants are commonplace procedures, as first described by Brånemark and colleagues.<sup>1</sup> The mandibular ramus is the preferred intra-oral donor site,<sup>2</sup> but the challenge to harvest an adequate quantity of bone with minimal risk of associated complications remains – particularly the risk of injury to the inferior alveolar nerve.

Measurements that are available in the literature have been derived in general from studies that use dry mandibles and from those that use harvested grafts; or otherwise have been applied to procedures other than grafting, such as sagittal split osteotomies.<sup>3-7</sup>

The advent of CBCT has greatly improved diagnostic imaging in the cranio-facial region. It not only allows accurate image production with reliable visualisation of the inferior alveolar nerve canal,<sup>8-10</sup> but its application also facilitates accurate measurements of alveolar bone.<sup>8-10</sup>

Clinically, application of these average values quantifying the location of the inferior alveolar nerve to the outer cortex of the mandible, in terms of height and width, will be invaluable in the prevention of untoward complications. This study uses cone-beam computed tomography (CBCT) to provide such average values.

1. **Sankeshan Padayachee:** BDS (Wits) MChD(UWC). Res. Department of Oral Medicine and Periodontics, University of the Western Cape Dental Faculty, Cape Town, South Africa.
2. **Haly Holmes:** BChD, MSc. MChD (UWC). Department of Oral Medicine and Periodontics, University of the Western Cape Dental Faculty, Cape Town, South Africa.
3. **Mohammed Ebrahim Parker:** BChD (UWC), MDent Rad(London), FICD. Department of Diagnostics and Radiology, University of the Western Cape Dental Faculty, Cape Town, South Africa.

### Corresponding author

**Sankeshan Padayachee:**

E-mail: drpaddy@thepodontist.co.za

## METHODS AND MATERIALS

A consecutive sample of 100 CBCT images of patients were obtained from the patient database of the Tygerberg Dental Hospital, University of the Western Cape. Ethical approval for the study was obtained from the University of the Western Cape Faculty and Senate Research Committees. The scans had been taken previously for diagnostic purposes, independent of this study. Anonymity of the patient was ensured as the patient image was allocated a number. Only the age and sex of the patient was recorded against the allocated number.

The unit information, technical settings and parameters had been set according to manufacturer specifications. Criteria for inclusion were patients above the age of 18 years (the age of complete development of the mandible).<sup>11</sup> Patient images were excluded from the study if the outer mandibular cortex and course of the inferior alveolar canal could not be clearly identified on the image or the image presented with impacted third molars, which resulted in distortion of reference points. The images of patients who had sustained trauma or presented with bony pathology that resulted in distortion or deformation of the mandibular anatomy (e.g. benign or malignant mandibular tumours), or of patients who had a history of previous maxillofacial surgery to the mandible in the vicinity of the inferior alveolar canal (e.g. patients with a history of bilateral sagittal split osteotomy, or who have had reconstruction plates placed), were also excluded.

The sample size was calculated from a test study. At  $n=100$  the standard error of the estimated mean was calculated to be 0.202 and the 95% confidence interval for the true mean was predicted to be approximately  $(M-0.40, M+0.40)$ , where  $M$  is the observed mean. The values were thus taken from 100 CBCT images.

CBCT software (Newtom VGi Image works Corps with QR-NNT<sup>®</sup> analysis software), was employed by a clinician to enhance visualisation of the inferior alveolar nerve and produce coronal slices at four defined points along the length of the inferior alveolar canal.

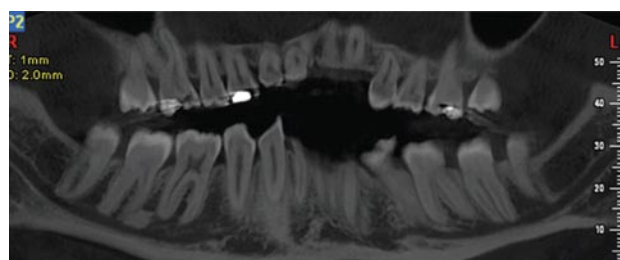


Figure 1: Reconstructed panoramic view using CBCT software displaying inferior alveolar nerve canal.

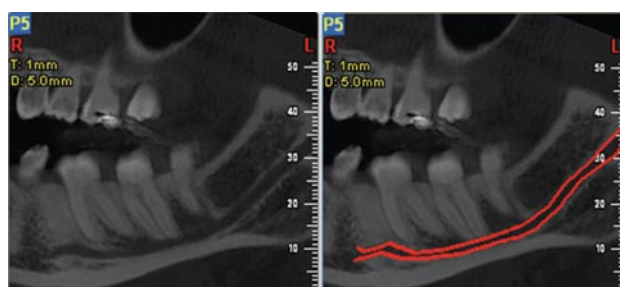


Figure 2: Traced boundaries of the inferior alveolar nerve canal on reconstructed panoramic views.

Each slice was set with a thickness of 1mm. The four points were defined at 10mm intervals anteriorly from the maximum convexity of the anterior border of the mandibular foramen (sections were made at points 10mm, 20mm, 30mm and 40 mm anterior to the mandibular foramen).

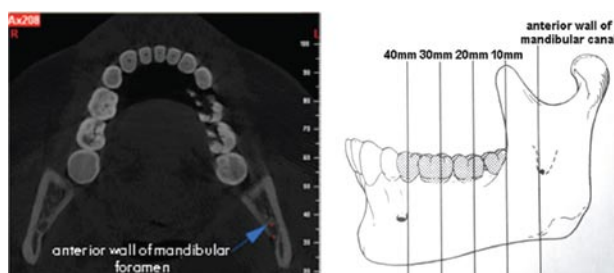


Figure 3&4: Anterior wall of the mandibular foramen identified on axial views. Four defined points at 10mm intervals..

At each point, measurements were obtained from the inferior alveolar canal to the outer aspect of the buccal cortex of the mandible and to the crest of the alveolar ridge (in edentulous mandibles) or the crest of the buccal cortical plate (in dentate mandibles). This was performed on both left and right sides of the mandible.

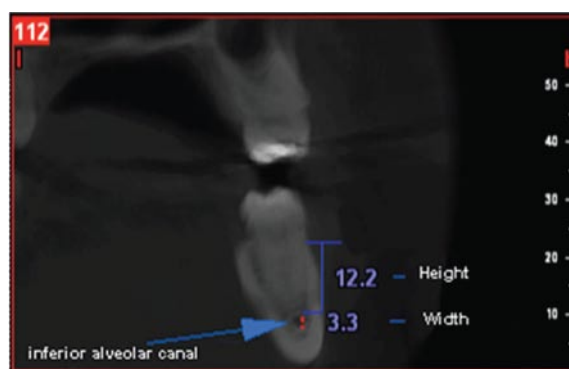


Figure 5: Coronal slice displaying the inferior alveolar nerve canal. Visualisation is enhanced by the red dots from outlining the nerve canal boundaries. Height and width measurements were made from this view.

The results were captured on the data collection sheet and values were transferred to a spreadsheet (Microsoft Excel<sup>®</sup>). Data were analysed using a standard statistic programme (Statistics R:R development Core Team 2013. R Foundation for Statistical Computing, Vienna, Austria; URL <http://www.R-project.org/>). The paired t-test was used to analyse right and left side measurements in order to test for differences in the means of the right and left sides.

## RESULTS

Table 1 below summarises the mean values from both left and right sides as well as the means of the combined values. Values that lay at or beyond the mental foramen were excluded from the overall mean calculations as these areas would be unsuitable for grafting. The paired t-test demonstrated that none of the differences between the means (between WL and WR, and between HL and HR) were found to be statistically significant ( $P < 0.05$ ). Figure 6 represents a plot of measurements for the widths on the right side (WR) matched with the widths on the left side (WR vs. WL) at the 10mm slice. As is apparent with this plot and similar plots at 20mm, 30mm and 40mm, the left and right side readings are not independent. Thus it was possible to combine left and right side results by obtaining the means of the pairs of every subject, consequently calculating summary statistics of these pairwise means. This is shown in Table 3.

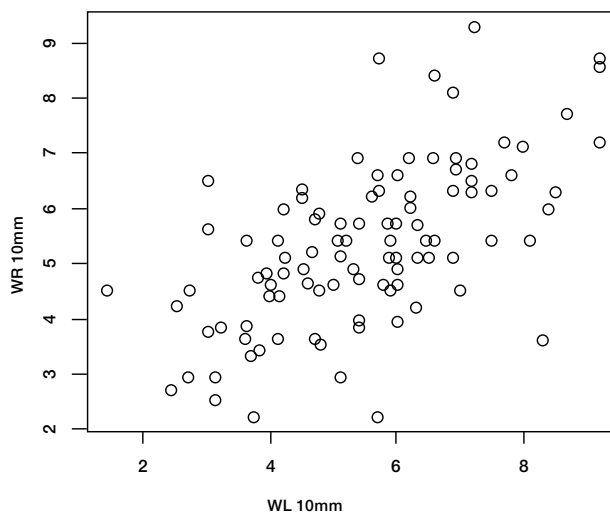
**Table 1:** Table of measurements and mean values

Points	WL	SD n value	HL	SD n value	WR	SD n value	HR	SD n value
10mm	5.499	±1.678 n=100	14.812	±4.689 n=100	5.322	±1.477 n=100	14.894	±4.114 n=100
20mm	6.606	±1.367 n=100	12.573	±3.507 n=100	6.444	±1.544 n=100	12.046	±4.108 n=100
30mm	6.748	±4.47 n=99	11.873	±3.972 n=99	6.087	±1.563 n=98	12.506	±4.413 n=97
40mm	5.182	±1.368 n=74	12.497	±4.043 n=74	5.145	±1.532 n=73	13.342	±4.051 n=73
Means of combined values	6.12	±1.899 n=100	12.978	±3.093 n=100	5.808	±1.185 n=100	13.158	±3.282 n=100

WL: Width on left side • WR: Width on right side • HL: Height on left side  
HR: Height on right side • SD: Standard deviation

The results of fitting the linear model indicated no interaction of the two factors. Fitting the model with no interaction gives the result shown in the following table (Table 4):

The H.all mean values (overall combined height) are greater for males than for females as shown by the positive co-efficient (2.647) for males in Table 4. This result is statistically significant (P-value<0.001). The effect of E on H.all shows that the value in edentulous patients is smaller, being marginally significant.



**Figure 6:** Plot of WR at 10mm vs. WL at 10mm showing that the plotted points lie close to one another confirming the validity of pooling the left and right samples.

**Table 2:** Combined results from left (L) and right (R) sides

Points	Mean width	SD n value	Mean height	SD n value
10mm	5.41	±1.417 n=100	14.853	±3.86 n=100
20mm	6.525	±1.26 n=100	12.31	±3.375 n=100
30mm	6.214	±1.368 n=98	12.233	±3.911 n=97
40mm	5.178	±1.244 n=65	13.185	±3.467 n=65
Means of combined values	5.891	±1.09 n=100	13.068	±2.963 n=100

SD: Standard deviation

The dependence of the overall combined mean width (see Table 2) on factors Edentulous (E)/Dentate (D) and Male (M)/Female (F) was examined by fitting a linear model with these factors and applying the combined mean width as the dependent variable. The results showed no significant effects of the factors.

This was similarly done for the overall combined height (see Table 2), with the combined mean height as a dependent variable. The means of the combined mean heights in the four categories are represented in Table 3.

**Table 3:** Comparison of heights (H.all)

Gender	Dentate (D)	Edentulous(E)
Female (F)	12.916 n=44	11.142 n=14
Male (M)	14.102 n=26	13.490 n=16

\*H.all represents the overall combined mean height

**Table 4:** Table of coefficients

	Estimate	Standard error	t value	Pr(>  t )
(intercept)	12.7806	0.4050	31.555	<2e-16***
Edent E	-1.2131	0.6309	-1.923	0.05744
Sex: Males	1.5504	0.5858	2.647	0.00948**

Asterisks in reference to significance level \*\*0.05 \*\*\*0.1

## DISCUSSION

The mandibular ramus is the preferred donor site when harvesting autogenous bone for the purpose of ridge augmentation, particularly owing to the higher risk of complications that are associated with symphyseal grafts.<sup>2,12</sup> During graft procedures, a lesser quantity of bone can be harvested from the ramus region than from the symphysis region due to anatomical limitations.<sup>13,14</sup> It is recommended that a larger graft volume should be harvested than is required, so as to compensate for any resorption that may occur.<sup>14</sup> Reports of resorption in volume are varied, ranging from volume 0%-46%.<sup>15-17</sup> This study aimed to provide average values that relate the inferior alveolar canal to the external cortex of the mandible, in both the horizontal and vertical planes, in the region of the mandible from which autogenous grafts are harvested. Knowledge of average values, as provided in our study, may prove useful in affording a greater thickness of bone that could potentially be harvested from the ramus. It would be ideal to harvest a graft that incorporates both adequate thickness and volume.

The widths (from the mandibular canal to the crest of the alveolar ridge) and the heights (from the external cortex to the mandibular canal in the horizontal plane) were measured at the four defined points along the canal. Our results reflected an average bone width of 5.891mm (±1.09) from the nerve canal to the outer cortex. The thickest amount of bone was found at the points representing 20mm and 30mm anterior to the mandibular foramen, measuring 6.21 mm and 6.53mm respectively.

During the harvest procedure as described by Misch,<sup>17</sup> four osteotomies are made and are referred to as the external oblique, the superior ramus, anterior body and inferior osteotomies (Figure 7).

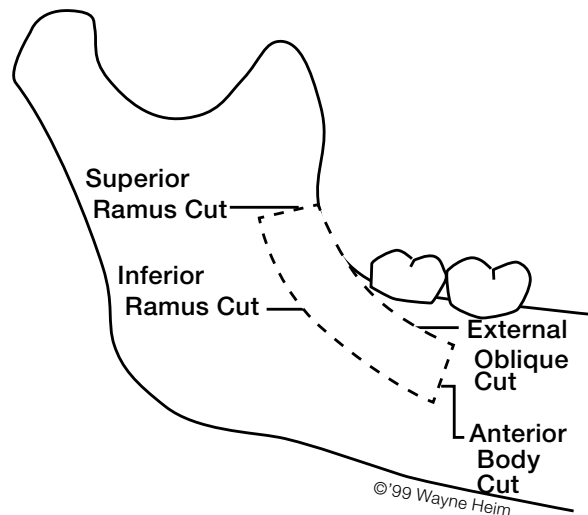
The external oblique cut, as described by Misch<sup>17</sup> commences where adequate thickness develops, made 3 to 5 mm medial to the external oblique ridge. The findings of this study are of particular significance during site mapping of these procedures, indicating adequate thickness to be present between the points representing 20mm and 30mm.

There have been several studies which attempt to provide parameters for a 'safe-zone' for surgical procedures in the mandibular ramus region. These attempts have been performed using cadaver mandibles<sup>3,4</sup> as well as on live patients from harvested grafts.<sup>5-7</sup> Values that are often referenced in both maxillofacial (for bilateral sagittal split osteotomy procedures) and in dental implant literature are from a study performed by Rajchel.<sup>4</sup> Those authors found that the bone adjacent to the inferior alveolar nerve was thickest in the first molar region of the mandible with a mean dimension of 5.95mm (4.05mm cancellous bone thickness and 1.9mm cortical bone thickness). Their results indicated that the safest zone lies in the first and second molar area. One must consider that their study was performed on 45 dry cadaveric mandibles. Shrinkage associated with the dry specimen is a plausible explanation for the discrepancy between Rajchel's findings and the results of this current study.

Another study investigating such values was conducted by Leong and co-workers,<sup>7</sup> who provide values on cortical thickness taken from harvested grafts. In their study, the thickness of the cortical plate is described as averaging 2.8mm in dentate and 2.5mm in edentulous jaws, and that was greatest in the second molar region. The authors concluded that a safe thickness for harvesting in the molar region was found at 2.5 to 3mm medial to the external surface of the cortical plate. The drawback in that research was that the marrow space was not easily preserved during the harvest procedure. Thus the distinct parameters of the marrow space, and in-turn, the complete cortico-cancellous component could not be adequately defined.

Computed tomography is a reliable and accurate means to locate the position of the mandibular canal and its relation to the outer cortex.<sup>18,19</sup> It overcomes disadvantages, such as shrinkage of dry skulls, fracture of subtle structures, magnification, distortion and questionable reproducibility of radiographic images, as has been shown in previous studies.<sup>20</sup>

The height value in the current study is an indication as to the depth of the inferior alveolar canal from the alveolar ridge crest. The results of this study reflect an overall mean height of 13.158mm ( $\pm 3.282$ ). A study that measured the height of bone above the inferior alveolar canal in the retromolar region using digital panoramic radiographs, found an average height of 11mm in that region.<sup>21</sup> This value from the retromolar region would fall between values taken at points 10mm and 20mm in this study, having heights of 14.85mm and 12.31mm respectively. Levine *et al.*<sup>22</sup> found an average height of 17.4mm to be present above the inferior alveolar nerve canal in the first molar



**Figure 7:** Diagrammatic representation of the four possible osteotomies defining the harvest procedure (Misch, CM<sup>17</sup>)

region, where measurements were taken from 50 CBCT scans. It may be assumed that, in our study, the first molar region is represented by the point at 30mm, having a height value of 12.33mm.

The values reflected in our results show the heights to be greater in males (14.102mm) than in females (12.916mm), the differences being marginally significant ( $p < 0.05$ ). Possibly, this discrepancy may be explained by anatomical differences between male and female jaws. From CBCT studies assessing the location of the inferior alveolar nerve canal in the ramus region for mandibular angle reduction surgery, anatomical differences in the location of the nerve between males and females have been described. Kane AA *et al.*,<sup>23</sup> found the nerve to be significantly deeper from the lateral cortex surface in females than in males. In males the nerve was found to be significantly closer to the anterior border of the ramus and farther from the posterior border than in females. Mandibular ramus sizes were also found to be larger in men than in woman in both width and oblique height in another study by Lo *et al.*<sup>24</sup> Contrastingly, however, Angel *et al.*<sup>25</sup> found that the relative location of the canal and its associated mental and mandibular foramina remained fairly constant between the sexes.

Although no significant difference was observed in the widths between dentate and edentulous samples in this region, the mean height value was lower in edentulous mandibles (11.142mm in females and 13.490mm in males) than in dentate mandibles (12.916mm in females and 14.102 in males). This is expected in accordance with the natural resorption pattern and loss of width and height with loss of the dentition.<sup>26</sup> After the dentition is lost, the resorption pattern in the mandible is centrifugal, becoming wider and shorter with time.<sup>27</sup>

This study utilised CBCT images, eliminating disadvantages such as shrinkage of dry skulls, fracture of subtle structures and differences due to magnification. However, certain inaccuracies concerned with mouse settings or operator tracing with the mouse may have been inherent in this study.

This study used points made at ten millimetre intervals from the mandibular foramen. In a study investigating similar dimensions, the teeth have been utilised as anatomical reference points.<sup>7</sup> Perhaps, correlation of the



points made at these intervals with anatomical landmarks would have enabled more substantial comparison between results. This may have also been better suited for anatomical application. Nevertheless, the values could still be applied clinically to assist the clinician, using the mandibular canal reference point. Also, this study aims to investigate the location of the mandibular canal and inferior alveolar nerve with relevance to mandibular ramus autogenous graft harvesting. In order to determine a safe-zone in which to harvest bone, one must also consider teeth that are present within the harvest site. This provides the suggestion that a similar study investigating the height and width of bone available to harvest from the mandibular ramus, including the teeth, would allow quantification of a safe zone. The results obtained in this study may provide useful values that can be used as a guide when harvesting autogenous grafts from the mandible. These values could also be extended to orthognathic surgical procedures as well as during planning for implant placement.

## CONCLUSION

This study aimed to measure the average distance from the outer cortex of the mandible to the inferior alveolar canal using CBCT in the mandibular molar region. The inferior canal may be located with a mean width of 5.891mm ( $\pm 1.09$ ) and mean height of 13.068mm ( $\pm 2.963$ ) from the external mandibular cortex. Mean height values are lower in edentulous mandibles and in females. The thickest amount of bone was found at the points representing 20mm and 30mm anterior to the mandibular foramen. This would be the safest zone when harvesting autogenous block grafts from the mandibular ramus region.

**Conflict of Interest:** None declared.

## References

- Brånemark PI, Lindstrom J, Hallén O, Breine U, Jeppson PH, Ohman A. Reconstruction of the defective mandible. *Scand J Plast Reconstr Surg.* 1975; 9(2):116-28
- Chiapasco M, Cansentini P, Zaniboni M. Bone augmentation procedures in implant dentistry. *Int J Oral Maxillofac Implants* 2009; 24(s) 237-59
- Carter RB and Keen EN. The intramandibular course of the inferior alveolar nerve. 1971. *J Anat*; 108(3): 433-40
- Rajchel J, Ellis E 3rd Fonseca RJ. The anatomical location of the mandibular: Its relationship to the sagittal ramus osteotomy. *Int J Adult Orthodon Orthognath Surg* 1986; 1:37-47
- Hwang KG, Shim KS, Yang SM, Park CJ. Partial thickness cortical bone graft from the mandibular ramus: A non-invasive harvesting technique. *J Periodontol* May 2008; 79:941-4
- Verdugo F, Simonian K, McDonald RS, Nowzari H. Quantitation of mandibular ramus volume as a source of bone grafting. *Clin Impl Dentistry and Related Res.* 2009. 11(s1):e32-e37
- Leong DJM, Li J, Moreno I, Wang H. Distance between external cortical bone and mandibular canal for harvesting ramus graft: A human cadaver study. *J Periodontol* Feb 2010; 81:239-43
- Oliveira-Santos C, Capelozza A, Dezotti MS, Fischer CM, Poleti ML, Rubira-Bullen IRF. Visibility of the mandibular canal on CBCT cross sectional images. *J Appl Oral Biol* 2011; 19(3):240-3
- Liang X, Lambrichts I, Sun Y, Denis K, Hassan B, Li L, Pauwels R, Jacobs R. A comparative evaluation of Cone Beam Computed Tomography (CBCT) and Multi-Slice CT (MSCT). Part II: On 3D model accuracy. *Eur J Radiol.* 2010 Aug; 75(2):270-4
- Kobayashi K, Shimoda S, Nakagawa, Yamamoto A. Accuracy in measurement of distance using limited cone-beam computerised tomography. *Int J Oral Maxillofac Implants* 2004; 19:229-31
- Op Heij DG, Opdebeek H, van Steenberghe, Quirynen M. Age as a compromising factor for implant insertion. *Periodontology* 2000. 2003; 33:172-84
- Clavero J, Lundgren S. Ramus or chin grafts for maxillary sinus inlay and onlay augmentation: Comparison of donor site morbidity and complications. *Clin Implant Dent Relat Res* 2003; 5:154-60
- Misch CM, Misch CE, Resnik R, Ismail YH. Reconstruction of maxillary alveolar defects with mandibular symphysis grafts for dental implants: A preliminary procedural report. *Int J Oral Maxillofac Implants.* 1992; 7:360-6
- Yates DM, Brockhoff HC, Finn R, Phillips C. Comparison of intra-oral harvest sites for cortico-cancellous bone grafts. *J Oral Maxillofac Surg.* 2013; 71:497-504
- Cordaro L, Torsello F, Chen S, Ganeles J, Brägger U, Hämmerle C. Implant-supported single tooth restorations in the aesthetic zone: Transmucosal and submerged healing provide similar outcome when simultaneous bone augmentation is needed. *Clin Oral Impl Res.* May 2013:1-7
- Sbordone L, Toti P, Menchini-Fabris GB, Sbordone C, Piombino P, Guidetti F. Volume changes of autogenous bone grafts after alveolar ridge augmentation of atrophic maxilla and mandibles. *Int J Oral Maxillofac Surg* 2009;38:1059-65
- Misch CM. Use of mandibular ramus as a donor site for onlay bone grafting. *J of Implantology.* 2000 Vol XXVI; 1:42-9
- Aalam AA and Nowzari H. Mandibular cortical bone grafts part 1: Anatomy, healing process and influencing factors. *Compendium.* April 2007; 28(4):206-13
- Timock AM, Cook V, McDonald T, Leo MC, Crowe J, Benninger BL, Covell DA. Accuracy and reliability of buccal bone height and thickness measurements from CBCT imaging. *Am J Orthod Dentofacial Orthop.* 2011; 140:734-44
- Yu IH, Wang YK. Evaluation of mandibular anatomy related to sagittal split ramus osteotomy using 3 dimensional computer tomography scan images. *Int J O Maxillofac Surg.* 2008; 37:521-52
- Nkenke E, Radespiel-Troger M, Wiltfang J, Schultze-Mosgau S, Winkler G, Neukam FW. Morbidity of harvesting of retromolar bone grafts. A prospective study. *Clin Oral Implants Res* 2002; 13:514-21
- Levine MH, Goddard AL, Dodson TB. Inferior alveolar nerve canal position: a clinical and radiographic study. *J Oral Maxillofac Surg.* 2007 Mar; 65(3):470-4
- Kane AA, Lo LJL, Chen YR, Hsu KH, Noordhoof MS. The course of the inferior alveolar nerve in the normal human mandibular ramus and in patients presenting for cosmetic reduction of the mandibular angle. *J Plastic and Reconstr. Surg.* Oct 2000; 106 (5):1162-76
- Lo LJ, Wong FH, Chen YR. The position of the inferior alveolar nerve at the mandibular angle: an anatomic consideration for aesthetic mandibular angle reduction. *Ann Plast Surg.* 2004 Jul; 53(1):50-5
- Angel JS, Mincer HH, Chaudhry J, Scarbecz M. Cone-beam computed tomography for analysing variations in inferior alveolar canal location in adults in relation to age and sex. *J Forensic Sci.* 2011 Jan; 56(1):216-9
- Fu JH, Wang HL. Horizontal bone augmentation: The decision tree. *Int J Periodontics Restorative Dent.* 2011; 31: 429-36
- Pietrokovski J, Starinsky R, Arensburg B, Kaffe I. Morphologic characteristics of bony edentulous jaws. *J Prosthodont.* 2007 Mar-Apr; 16(2):141-7