
Randomized Controlled Trial (RCT)

Scandcleft randomized trials of primary surgery for unilateral cleft lip and palate: dental anomalies in 8-year olds

Sara Rizell^{1,○}, Haydn Bellardie^{2,3}, Agneta Karsten^{4,○}, Paul Sæle⁵, Jeanette Mooney², Arja Heliövaara⁶, Annelise Küsel⁷, Eli Brinck⁸, Pål Skaare⁸, Kirsten Mølsted⁹, Midia Najar Chalien¹, Agneta Marcusson¹⁰, Phil Eyres², W. Shaw² and Gunvor Semb^{2,8}

¹Department of Orthodontics, Institute of Odontology, Sahlgrenska Academy, University of Gothenburg, Sweden, ²Greater Manchester Cleft Lip and Palate Unit, Royal Manchester Childrens' Hospital, UK, ³Department of Orthodontics and Paediatric Dentistry, The University of the Western Cape, Cape Town, South Africa, ⁴Stockholm Craniofacial Team, Section for Orthodontics, Division of Orthodontics and Pedodontics, Department of Dental Medicine, Karolinska Institutet, Stockholm, Sweden, ⁵Oral Health Center of Expertise, Western Norway, Bergen, Norway, ⁶Cleft Palate and Craniofacial Center, Department of Plastic Surgery, Helsinki University Hospital, Finland, ⁷Cleft Palate Center and University Hospital Aarhus and University of Aarhus, Denmark, ⁸Department of Plastic and Reconstructive Surgery, Oslo University Hospital, Rikshospitalet, Norway, ⁹Copenhagen Cleft Palate Center, University Hospital of Copenhagen, Denmark, ¹⁰Department of Dentofacial Orthopedics, Maxillofacial Unit, University Hospital, Linköping, Sweden

Correspondence to: Sara Rizell, Orthodontic Clinic, University Clinics of Odontology, P.O. Box 7163, SE-402 33 Gothenburg, Sweden. E-mail: sara.rizell@vgregion.se

Summary

Background: Children born with unilateral cleft lip and palate (UCLP) are reported to display several dental anomalies including agenesis, supernumeraries, as well as variations in dental size, shape, and path of eruption. The extensive sample of individuals with UCLP included in the Scandcleft randomized control trials offers the opportunity to study more rare conditions, which is seldom possible with limited samples.

Objectives: The aim was to study dental anomalies at 8 years of age in children born with UCLP included in the Scandcleft randomized control trials.

Methods: Panoramic and intraoral radiographs from 425 individuals (279 males and 146 females) with a mean age of 8.1 years were assessed by four orthodontists regarding dental anomalies.

Results: Agenesis was found in 52.5 per cent and supernumerary teeth in 16.9 per cent of the participants. The cleft lateral was missing in 43.8 per cent and was found peg shaped in 44.7 per cent. The distribution of ectopic eruption was 14.6 per cent, mainly affecting maxillary first molars, while transposition was found in 3.4 per cent of the individuals. In addition, infraocclusion of one or several primary molars was registered in 7.2 per cent of the participants.

Conclusion: We conclude that 8-year-old children born with UCLP display multiple dental anomalies. The Scandcleft sample allowed rarely studied conditions such as infraocclusion of primary molars and transposition to be studied in children born with UCLP.

Trial registration: ISRCTN29932826.

Introduction

It is well known that children born with non-syndromic unilateral cleft lip and palate (UCLP) have a markedly higher frequency of different dental anomalies compared to the general population (1–6). These anomalies affect the number of teeth as well as size, shape, position, and eruption, both in the primary and the permanent dentition (7). The traits are commonly described in the cleft area but also outside the cleft and in the mandible (8, 9). One of the more common anomalies is dental agenesis, which is reported in 40–61 per cent for children born with UCLP (2, 10–12). The most frequently described missing tooth is the cleft lateral, which is absent in 47–59 per cent (5, 9, 13–16). Examples of other frequently reported conditions are supernumeraries, atypical dental anatomy, and ectopic eruption (5, 10, 17–20).

The Scandleft randomized trials were initiated in 1997 as three different trials for comparison between one common protocol for primary surgery and three local surgical protocols (21). The overall objectives for the trials were to test if variations in surgical technique and staging for children with UCLP were associated with outcome. Several reports have been published concerning the primary outcomes, speech, and dentofacial development (21–25). With the prospective design, the Scandleft material brings about a unique possibility to study secondary outcomes in a substantial and well-defined sample. To our knowledge, there are no other studies on dental anomalies in such an extensive group of individuals born with complete UCLP.

Aim

The aim was, therefore, to study dental anomalies at eight years of age in children born with UCLP included in The Scandleft randomized trials.

Subjects and methods

Four hundred and twenty-nine Caucasian individuals with non-syndromic complete UCLP from nine cleft centres in Scandinavia and Great Britain were included in the Scandleft Trials (21). Those with a Simonart's band of less than 5 mm were included. Out of this group, three individuals missed records and one was late diagnosed with a syndrome; therefore, 425 individuals finally were included in this part of the project (flow chart enclosed as [Supplementary material](#)). The participants consisted of 279 males and 146 females with a mean age of 8.1 and median age of 8.0 years (5.0–10.6 years). Digital or scanned panoramic radiographs, taken at 8 years of age, were collected from the participating centres. In addition, intraoral radiographs from the cleft area were available in the vast majority of the cases, while, in a minor portion, we instead had access to cone beam computed tomography (CBCT). The radiographs were obtained prior to orthodontic treatment and bone grafting. The assessments were made independently, by four experienced orthodontists, situated in different locations. However, in cases where the group disagreed, a consensus agreement was worked out. Variables as agenesis and supernumeraries of permanent teeth, shape and position of cleft lateral, ectopic eruption, transposition, and infraocclusion were assessed. Eventual third molars were excluded from any assessment. Since 8 years is considered early for a secure diagnosis of posterior agenesis, later available radiographs were used for confirmation. To ensure that no extractions were performed prior to the panoramic radiograph, the medical records were reviewed. For the variables ectopic eruption, transposition, and infraocclusion, only

radiographs obtained at 8 years \pm 6 months were used ($n = 376$). Infraocclusion was registered when a primary molar failed to reach the occlusal plane with ≥ 2 mm. Transposition was defined as a positional interchange of two adjacent teeth and especially their roots. The results will be presented for the total group, irrespective of the surgical protocol to which the individuals were allocated. The distribution of the variables between cleft side and gender were tested with Fisher's exact test. The results were pooled for the remaining variables and will be presented with descriptive statistics as one group as no differences were found for either gender or cleft side, except for the variable infraocclusion.

The research protocol was approved by all centres and local ethical approvals were obtained (Denmark 1997/4121, Finland 4/9/97, Norway S-97152, Manchester 99/197, Sweden 97–372, and R257-97). Principles outlined in the Declaration of Helsinki were followed.

Results

Agenesis of one or several teeth was found in 52.5 per cent of the participants and the distribution of affected teeth is shown in [Table 1](#). The majority of the individuals with agenesis were missing only one single tooth (36.0 per cent), but the number of missing teeth ranged from one to as many as 14 teeth ([Figure 1](#)). The most commonly affected tooth was the cleft lateral, which was missing in 43.8 per cent of the participants, while the non-cleft lateral was absent in only 4.5 per cent ([Table 1](#)). The second premolar was affected in 17.9 per cent of the individuals with a range of one to four maxillary and/or mandibular teeth being absent ([Table 1](#) and 2).

Supernumerary teeth were found in 16.9 per cent of the participating individuals and the most commonly affected tooth was the cleft lateral ([Table 1](#)). In 14.3 per cent of the sample, the supernumerary lateral was located on the cleft side; in 0.7 per cent of the cases, it was found on the non-cleft side; and in another 0.5 per cent of the individuals, a supernumerary lateral was located bilaterally. A mesiodens was found in 1.2 per cent of the participants ([Table 1](#)).

Table 1. Prevalence of agenesis and supernumerary teeth in individuals with unilateral cleft lip and palate participating in the Scandleft randomized control trials

Numerary anomalies		Number of individuals <i>n</i> = 425	Frequency (%)
Agenesis	Agenesis	223	52.5
	Cleft lateral	186	43.8
	Non-cleft lateral	19	4.5
	Bilateral maxillary laterals	14	3.3
	Maxillary central	6	1.4
	Maxillary/mandibular second premolar	76	17.9
	Maxillary/mandibular molar	8	1.9
	Mandibular agenesis	47	11.1
Supernumeraries	Lateral (only)	65	15.3
	Mesiodens	5	1.2
	Mandibular incisor	1	0.2
	Lateral + mesiodens + 44	1	0.2
	Total of individuals with supernumeraries	72	16.9

A portion of the included individuals expressed more than one of the described traits for agenesis, why the total sum exceeds 100%.

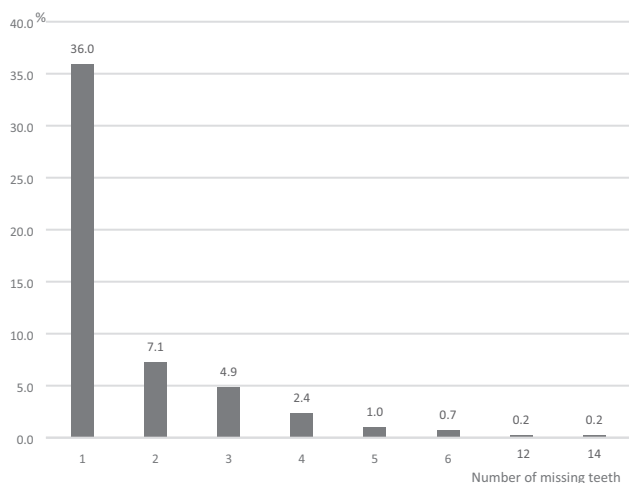


Figure 1. Distribution of the number of missing teeth in individuals with unilateral cleft lip and palate participating in Scandcleft randomized control trials.

Table 2. Aggenesis of second premolars (number and location) in individuals with unilateral cleft lip and palate participating in the Scandcleft randomized control trials

		Number of individuals <i>n</i> = 425	Frequency (%)
Agenesis of second premolars			
Number of missing second premolars	One premolar	37	8.7
	Two premolars	24	5.7
	Three premolars	9	2.1
	Four premolars	6	1.4
	Total	76	17.9
Location of second premolar aggenesis	Agenesis of maxillary second premolars	37	8.7
	Agenesis of mandibular second premolars	19	4.5
	Agenesis of maxillary and mandibular second premolars	20	4.7
	Total	76	17.9

In our sample, the cleft lateral was judged to be peg shaped in 44.7 per cent of the individuals and additional 4.0 per cent showed other malformations (Table 3). The lateral was positioned distally to the cleft in 31.8 per cent, mesial to the cleft in 9.4 per cent, and on each side of the cleft (i.e., where a supernumerary lateral was present) in 15.0 per cent of the cases (Table 3).

The distribution of ectopic eruption was 14.6 per cent (Table 4). One or both of the maxillary first molars erupted ectopically in 10.3 per cent of the participants (Table 4). In addition, 6.9 per cent of the individuals in our sample showed signs of reversible ectopic eruption of the maxillary first molars (Table 4). A transposition was found in 3.4 per cent of the individuals, mainly affecting the maxillary canine and first premolar (Table 4). The frequency of infraocclusion of primary molars was 7.2 per cent and the number of affected teeth ranged from one to six (Table 4). Out of 27 individuals, who were diagnosed with infraocclusion, 20 exhibited infraoccluded mandibular primary molars and two exhibited maxillary primary

Table 3. Prevalence of variations in shape and position of the permanent cleft lateral in individuals with unilateral cleft lip and palate participating in the Scandcleft randomized control trials

	Number of individuals <i>n</i> = 425	Frequency (%)
Cleft lateral shape		
Peg shaped	190	44.7
Other malformation	17	4.0
Normal	32	7.5
Agenesis	186	43.8
Cleft lateral position		
Distal to cleft	135	31.8
Mesial to cleft	40	9.4
Lateral on each side of the cleft (i.e. present cleft side supernumerary)	64	15.0
Agenesis	186	43.8

Table 4. Prevalence of ectopic eruption, transposition, and infraocclusion of primary molars in individuals with unilateral cleft lip and palate participating in the Scandcleft randomized control trials.

		Number of individuals <i>n</i> = 376	Frequency (%)
Eruption disturbances			
Ectopic eruption	Unilateral maxillary molar	32	8.5
	Bilateral maxillary molars	7	1.8
	Maxillary central	9	2.4
	Maxillary lateral	1	0.3
	Maxillary canine	4	1.1
	Mandibular molar	2	0.5
	Total	55	14.6
Reversible ectopic eruption	Unilateral maxillary molar	19	5.0
	Bilateral maxillary molar	7	1.9
	Total	26	6.9
Transposition	Maxillary canine/first premolar unilateral	10	2.6
	Maxillary canine/first premolar bilateral	2	0.5
	Other	1	0.3
	Total	13	3.4
	Infraocclusion	One affected tooth	13
Two affected teeth	8	2.1	
Three affected teeth	2	0.5	
Four affected teeth	3	0.8	
Six affected teeth	1	0.3	
Total	27	7.2	

molars, whilst five individuals had infraoccluded maxillary as well as mandibular primary molars. The total number of infraoccluded primary molars in the sample was 53 (37 first primary and 16 second primary molars). Eight out of these infraoccluded teeth displayed aggenesis of the permanent successor. Infraocclusion was the only variable where a statistically significant gender difference was found and females exhibited a higher frequency than males (12.3 versus 4.4 per cent, $P < 0.05$).

Atypical anatomy of the centrals was the most striking other anomaly detected in this sample, where underdeveloped crowns,

Table 5. Prevalence of other dental anomalies in individuals with unilateral cleft lip and palate participating in the Scandcleft randomized control trials.

Other anomalies	Number of individuals <i>n</i> = 425	Frequency (%)
Dental anatomy/development		
Cleft central malformed	11	2.6
Cleft central atypical crown-root angulation	8	1.9
Cleft central microdontia	5	1.2
Atypical tooth anatomy outside cleft area	7	1.6
Position		
Inverted mesiodens or lateral	5	1.2
Other		
Condylar hypoplasia non-cleft side	1	0.2
Cleft area odontoma	1	0.2

extra cusps, as well as loss of hard tissue were seen (Table 5). In addition, disturbances of dental development, positional deviations, and more rare conditions such as condylar hypoplasia and cleft area odontoma occurred (Table 5).

Discussion

This study was undertaken to reveal the distribution of different dental anomalies in individuals born with UCLP, participating in the Scandcleft trials. The traits studied in this project were hypodontia, supernumeraries, atypical dental shape, lateral position, ectopic eruption, transposition, and infraocclusion. The sample of individuals born with UCLP showed a wide range of dental anomalies.

Agenesis

The number of individuals in this project exhibiting agenesis of one single or multiple teeth was 52.5 per cent (Table 1). This figure corresponds well with previous published results for individuals with UCLP (2, 10–13, 26). The cleft lateral is reported to be the most commonly missing tooth and the frequency of 43.7 per cent missing cleft laterals confirms earlier findings (Table 1) (5, 9, 11–16, 18, 19, 27). In addition, agenesis of premolars was recorded in 17.9 per cent of the participants in The Scandcleft Trials, which is within the range of previously reported results of 15–20 per cent for individuals born with UCLP (Tables 1 and 2) (8, 27).

The etiology of hypodontia in UCLP is claimed to be multifactorial and is still under investigation. It has been suggested that the primary repair affects dental development and that disturbances in the intraoral environment, as defects in mesenchymal tissue or blood supply, could be other plausible factors (12, 28). However, familial studies have shown that siblings and parents to children with clefts have a significantly higher frequency of agenesis than non-cleft individuals and claim support for the hypothesis of a common genetic link between cleft and dental anomalies (29, 30). In addition, individuals born with UCLP in combination with agenesis of the cleft lateral exhibited a higher frequency of non-cleft agenesis compared to individuals with UCLP combined with a present cleft lateral (11). The group thereby draws the conclusion that absence of the cleft lateral is a result from a largely genetically controlled anomaly associated with cleft development rather than an environmental consequence. An association between tooth agenesis inside and outside the

cleft and disturbances of the genes *MSX1* as well as *PAX9* has been stated (31, 32). Evidence has also been presented for *IRF6*, *ANKS6*, and *ERBB2* being common genetic factors associated with both oral clefts and dental anomalies (33–35).

Supernumerary teeth

In 16.9 per cent of the individuals, one or several permanent supernumerary teeth were found, most commonly in the cleft area (Table 1). The frequencies of supernumeraries earlier reported in the literature range from 10 to 25 per cent (5, 10, 18, 19, 26). The wide range reported might reflect the difficulty of diagnosing supernumerary teeth in the cleft area. There are suggestions that the interrupted fusion of the medial nasal and maxillary processes results in a separation of the dental epithelia, which causes the formation of two laterals (36). In addition, a linkage between the aberrations on chromosome 1 and a cleft as well as supernumerary teeth has been discussed (37).

Shape and position of cleft lateral

The cleft lateral was recorded as peg shaped in almost 45 per cent of the individuals in the present sample. In an additional 4 per cent of cases, the lateral expressed other developmental anomalies (Table 3). These are commonly described phenomenon among children born with UCLP (36). Variability in how a ‘peg-shaped’ lateral is defined and differences in study design can account for the variation in reported frequencies. Some authors have assessed radiographs solely, whilst others have added cast models for the recordings. The cleft lateral was positioned distally to the cleft in a majority of the cases, confirming earlier results (Table 3) (9, 11, 18).

Ectopic eruption

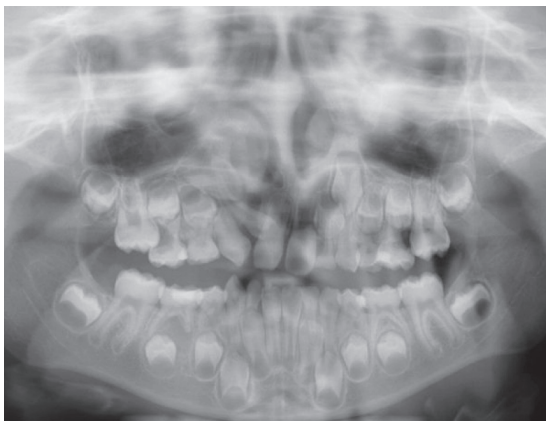The maxillary first molars, either unilateral or bilateral, were the most common ectopically erupting teeth, that is, 10.3 per cent among our sample (Table 4). Including molars with reversible ectopic eruption, the figure for ectopic first molar eruption is 17.2 per cent (Table 4). Reversible ectopic eruption of maxillary first molars has been described as a condition where the permanent molar frees itself from the resorption cavity of the second primary molar (Figure 2) (38). Previous reports have shown ectopic maxillary molars in around 20 per cent for 6–8-year-old children with different kinds of cleft types and discuss both local and genetic factors as plausible etiology (17, 39). The maxillary length (pm-ss) has been found to correlate with ectopic maxillary molars in individuals with clefts (40) and, since a familial tendency was found in a non-cleft sample, a genetic influence has been discussed (41). Since we know that a portion of molars displaying ectopic eruption will correct spontaneously, it is important to highlight that the figures we present are representative only for 8 years.

Ectopic eruption of maxillary canines was only found in 1.1 per cent in our sample. This is evidently lower than previous reports with 15–20 times higher figures (5, 42, 43). However, the participants in our study were only 8 years of age with radiographs obtained before bone grafting, which might explain the distribution of a high number of ectopic maxillary molars and a lower number of ectopic canine eruption.

Transposition

We found a frequency of transposition of 3.4 per cent, mainly affecting maxillary canines and first premolars, while other studies have found higher figures (44–46). The younger age of the present sample might be a plausible explanation for the diverging rates. It is important to bear in mind that the figures we present are radiological

(A)



(B)

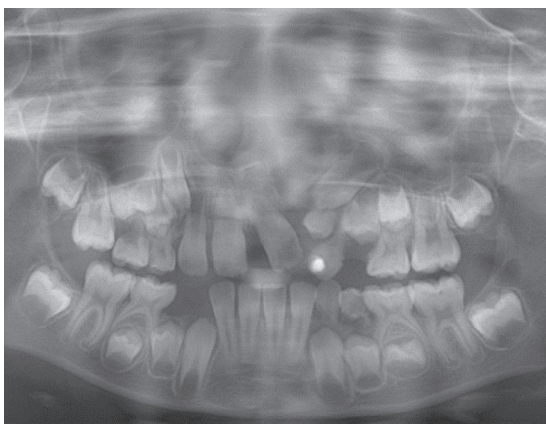


Figure 2. (A) Example of ectopic eruption of right-side maxillary first molar. (B) Example of reversible ectopic eruption of right-side maxillary first molar.

signs of a transposition at 8 years and do not implicate that these teeth finally erupted in a clinical transposition.

Infraocclusion

Infraocclusion of primary molars is judged to reach a maximum at around 8–9 years of age in non-cleft children, with a wide range from 5 to 22 per cent reported (47–49). Infraocclusion of one or more primary molars occurred in 7.2 per cent in the 8-year Scandcleft sample (Table 4). To our knowledge, no results concerning this condition in children with cleft lip and palate has been reported. The association between infraocclusion of primary molars and other dental anomalies in non-cleft individuals has been highlighted and common causal genetic factors have been discussed (48, 50). It is suggested that infraocclusion of primary molars is an early marker for later appearing dental anomalies as tooth agenesis and palatally displaced canines (50). However, only 8 out of 53 infraoccluded primary molars were associated with agenesis of the permanent successor the present sample.

Other anomalies

Malformed central incisors, including microdontia, or deviating crown-root angulation were recorded in 5.7 per cent of the participants (Table 5). This is supported by previous reports of different

kinds of cleft central malformations (51–53). Rare conditions as agenesis of the cleft side condyle or odontoma in the cleft area was also noted (Table 5).

In comparison with non-cleft individuals, several of the studied variables are more frequently found in children born with UCLP. Agenesis has been reported in 4.5–7.4 per cent in Scandinavian school children, while we found 52.5 per cent in our sample of UCLP (4, 54, 55). The occurrence of agenesis is found to be increased for different types of clefts but seem to be more pronounced in complete unilateral clefts (56). In addition, traits as supernumeraries, microdontia, impaction, and transposition occur more commonly in individuals with different types of clefts compared to individuals without cleft (56).

The individuals in the present study were 8 years of age and it is well known that, at this early age, diagnosis of late-developing premolars and second molars is not reliable. To minimize bias from a false diagnosis of agenesis, missing premolars and molars were ensured by adding assessment from later radiographs. In addition, to exclude bias from early extractions of permanent teeth, information from patient files was obtained in cases with missing centrals and/or molars. One of the participants was found to have had both mandibular first molars extracted, and one case lost a maxillary central incisor due to trauma. Accurate diagnosis of dental anomalies in the cleft area can be demanding due to atypical tooth anatomy and presence of supernumerary teeth. The assessments were made by four orthodontists with more than 10 years experience of collaboration in a cleft team. Despite the aggregated experience, the assessments diverged in particular cases. However, we interpret the preparation of a consensus agreement to have decreased the risk of false results since mistakes due to inattention have been avoided.

Assessment of dental shape by using 2D radiographs might be considered hazardous. More ideal methods would have been using 3D radiology as CBCT or clinical assessment after eruption. However, the use of CBCT has disadvantages, such as the radiation dose, but might be an alternative for future research. The results describing lateral shape should, therefore, be interpreted with caution but gives an indication about the condition.

The prospective multicenter design of the project meant that a substantial sample could be collected within a reasonable time period and that a controlled inclusion of participants could be secured. In addition, an extended group of participants allowed assessment of conditions that normally are too rare to be studied in limited samples. Examples such as the variables infraocclusion and transposition in individuals born with UCLP are rare anomalies, present only in a limited group of patients and, therefore, seldom studied.

Conclusion

In this prospective sample of children born with UCLP included in the Scandcleft randomized control trials, a large number of dental anomalies were found. The results confirm earlier findings and we conclude that 8-year-old children born with UCLP display multiple dental anomalies. The multicenter design resulted in a substantial sample with a limited age span, which allowed rare conditions such as infraocclusion of primary molars and transposition to be studied.

Supplementary material

Supplementary data are available at the *European Journal of Orthodontics* online.

Conflicts of interest

The authors report no conflicts of interest. The authors alone are responsible for the content and writing of this paper.

References

- Menezes, R. and Vieira, A.R. (2008) Dental anomalies as part of the cleft spectrum. *The Cleft Palate Craniofacial Journal*, 45, 414–419.
- Sá, J., Araújo, L., Guimarães, L., Maranhão, S., Lopes, G., Medrado, A., Coletta, R. and Reis, S. (2016) Dental anomalies inside the cleft region in individuals with nonsyndromic cleft lip with or without cleft palate. *Medicina Oral, Patologia Oral y Cirugía Bucal*, 21, e48–e52.
- Tannure, P.N., Oliveira, C.A., Maia, L.C., Vieira, A.R., Granjeiro, J.M. and Costa, M.d.e.C. (2012) Prevalence of dental anomalies in nonsyndromic individuals with cleft lip and palate: a systematic review and meta-analysis. *The Cleft Palate Craniofacial Journal*, 49, 194–200.
- Thilander, B. and Myrberg, N. (1973) The prevalence of malocclusion in Swedish schoolchildren. *Scandinavian Journal of Dental Research*, 81, 12–21.
- Tortora, C., Meazzini, M.C., Garattini, G. and Brusati, R. (2008) Prevalence of abnormalities in dental structure, position, and eruption pattern in a population of unilateral and bilateral cleft lip and palate patients. *The Cleft Palate Craniofacial Journal*, 45, 154–162.
- Riis, L.C., Kjær, I. and Mølsted, K. (2014) Dental anomalies in different cleft groups related to neural crest developmental fields contributes to the understanding of cleft aetiology. *Journal of Plastic Surgery and Hand Surgery*, 48, 126–131.
- Camporesi, M., Baccetti, T., Marinelli, A., Defraia, E. and Franchi, L. (2010) Maxillary dental anomalies in children with cleft lip and palate: a controlled study. *International Journal of Paediatric Dentistry*, 20, 442–450.
- Mikulewicz, M., Ogiński, T., Gedrange, T., Berniczki-Royko, A. and Prusak, E. (2014) Prevalence of second premolar hypodontia in the Polish cleft lip and palate population. *Medical Science Monitor*, 20, 355–360.
- Tsai, T.P., Huang, C.S., Huang, C.C. and See, L.C. (1998) Distribution patterns of primary and permanent dentition in children with unilateral complete cleft lip and palate. *The Cleft Palate Craniofacial Journal*, 35, 154–160.
- Al-Kharboush, G.H., Al-Balkhi, K.M. and Al-Moammar, K. (2015) The prevalence of specific dental anomalies in a group of Saudi cleft lip and palate patients. *The Saudi Dental Journal*, 27, 75–80.
- Dentino, K.M., Peck, S. and Garib, D.G. (2012) Is missing maxillary lateral incisor in complete cleft lip and palate a product of genetics or local environment? *The Angle Orthodontist*, 82, 959–963.
- Ranta, R. (1986) A review of tooth formation in children with cleft lip/palate. *American Journal of Orthodontics and Dentofacial Orthopedics*, 90, 11–18.
- Bøhn, A. (1950) Anomalies of the lateral incisor in cases of harelip and cleft palate. *Acta Odontologica Scandinavica*, 9, 41–59.
- Baek, S.H. and Kim, N.Y. (2007) Congenital missing permanent teeth in Korean unilateral cleft lip and alveolus and unilateral cleft lip and palate patients. *The Angle Orthodontist*, 77, 88–93.
- Dewinter, G., Quirynen, M., Heidbüchel, K., Verdonck, A., Willems, G. and Carels, C. (2003) Dental abnormalities, bone graft quality, and periodontal conditions in patients with unilateral cleft lip and palate at different phases of orthodontic treatment. *The Cleft Palate Craniofacial Journal*, 40, 343–350.
- Lourenço Ribeiro, L., Teixeira Das Neves, L., Costa, B. and Ribeiro Gomide, M. (2003) Dental anomalies of the permanent lateral incisors and prevalence of hypodontia outside the cleft area in complete unilateral cleft lip and palate. *The Cleft Palate Craniofacial Journal*, 40, 172–175.
- Bjerklin, K., Kurol, J. and Paulin, G. (1993) Ectopic eruption of the maxillary first permanent molars in children with cleft lip and/or palate. *European Journal of Orthodontics*, 15, 535–540.
- Pegelow, M., Alqadi, N. and Karsten, A.L. (2012) The prevalence of various dental characteristics in the primary and mixed dentition in patients born with non-syndromic unilateral cleft lip with or without cleft palate. *European Journal of Orthodontics*, 34, 561–570.
- Yatabe, M.S., Garib, D.G., Janson, G., Poletto, R.S. and Ozawa, T.O. (2013) Is the presence of Simonart's band in patients with complete unilateral cleft lip and palate associated with the prevalence of missing maxillary lateral incisors? *American Journal of Orthodontics and Dentofacial Orthopedics*, 144, 649–653.
- Carr, G.E. and Mink, J.R. (1965) Ectopic eruption of the first permanent maxillary molar in cleft lip and cleft palate children. *Journal of Dentistry for Children (Chicago, Ill.)*, 32, 179–188.
- Semb, G., et al. (2017) A Scandcleft randomised trials of primary surgery for unilateral cleft lip and palate: 1. Planning and management. *Journal of Plastic Surgery and Hand Surgery*, 51, 2–13.
- Heliövaara, A., et al. (2017) Scandcleft randomised trials of primary surgery for unilateral cleft lip and palate: 6. Dental arch relationships in 5 year-olds. *Journal of Plastic Surgery and Hand Surgery*, 51, 52–57.
- Karsten, A., et al. (2017) Scandcleft randomised trials of primary surgery for unilateral cleft lip and palate: 7. Occlusion in 5 year-olds according to the Huddart and Bodenham index. *Journal of Plastic Surgery and Hand Surgery*, 51, 58–63.
- Mølsted, K., et al. (2017) Scandcleft randomised trials of primary surgery for unilateral cleft lip and palate: 8. Assessing naso-labial appearance in 5-year-olds - a preliminary study. *Journal of Plastic Surgery and Hand Surgery*, 51, 64–72.
- Willadsen, E., et al. (2017) Scandcleft randomised trials of primary surgery for unilateral cleft lip and palate: 5. Speech outcomes in 5-year-olds—consonant proficiency and errors. *Journal of Plastic Surgery and Hand Surgery*, 51, 38–51.
- Sæle, P., Østhus, E., Ådalen, S., Nasir, E.F. and Mustafa, M. (2017) Pattern of clefts and dental anomalies in six-year-old children: a retrospective observational study in western Norway. *Acta Odontologica Scandinavica*, 75, 100–105.
- Shapira, Y., Lubit, E. and Kufnec, M.M. (2000) Hypodontia in children with various types of clefts. *The Angle Orthodontist*, 70, 16–21.
- Howe, B.J., Cooper, M.E., Vieira, A.R., Weinberg, S.M., Resick, J.M., Nidey, N.L., Wehby, G.L., Marazita, M.L. and Moreno Uribe, L.M. (2015) Spectrum of dental phenotypes in nonsyndromic orofacial clefting. *Journal of Dental Research*, 94, 905–912.
- Eerens, K., Vlietinck, R., Heidbüchel, K., Van Olmen, A., Derom, C., Willems, G. and Carels, C. (2001) Hypodontia and tooth formation in groups of children with cleft, siblings without cleft, and nonrelated controls. *The Cleft Palate Craniofacial Journal*, 38, 374–378.
- Küchler, E.C., da Motta, L.G., Vieira, A.R. and Granjeiro, J.M. (2011) Side of dental anomalies and taurodontism as potential clinical markers for cleft subphenotypes. *The Cleft Palate Craniofacial Journal*, 48, 103–108.
- Seo, Y.J., Park, J.W., Kim, Y.H. and Baek, S.H. (2013) Associations between the risk of tooth agenesis and single-nucleotide polymorphisms of MSX1 and PAX9 genes in nonsyndromic cleft patients. *The Angle Orthodontist*, 83, 1036–1042.
- Modesto, A., Moreno, L.M., Krahn, K., King, S. and Lidral, A.C. (2006) MSX1 and orofacial clefting with and without tooth agenesis. *Journal of Dental Research*, 85, 542–546.
- Vieira, A.R., McHenry, T.G., Daack-Hirsch, S., Murray, J.C. and Marazita, M.L. (2008) A genome wide linkage scan for cleft lip and palate and dental anomalies. *American Journal of Medical Genetics. Part A*, 146A, 1406–1413.
- Letra, A., et al. (2012) Interaction between IRF6 and TGFA genes contribute to the risk of nonsyndromic cleft lip/palate. *PLoS One*, 7, e45441.
- Chu, E.Y., et al. (2016) Full spectrum of postnatal tooth phenotypes in a novel Irf6 cleft lip model. *Journal of Dental Research*, 95, 1265–1273.
- Hovorakova, M., Lesot, H., Peterkova, R. and Peterka, M. (2006) Origin of the deciduous upper lateral incisor and its clinical aspects. *Journal of Dental Research*, 85, 167–171.
- Yildirim, M., Seymen, F., Deeley, K., Cooper, M.E. and Vieira, A.R. (2012) Defining predictors of cleft lip and palate risk. *Journal of Dental Research*, 91, 556–561.
- Bjerklin, K. and Kurol, J. (1981) Prevalence of ectopic eruption of the maxillary first permanent molar. *Swedish Dental Journal*, 5, 29–34.

39. da Silva Filho, O.G., De Albuquerque, M.V. and Kurol, J. (1996) Ectopic eruption of maxillary first permanent molars in children with cleft lip. *The Angle Orthodontist*, 66, 373–380.
40. Bjerklin, K. and Kurol, J. (1983) Ectopic eruption of the maxillary first permanent molar: etiologic factors. *American Journal of Orthodontics*, 84, 147–155.
41. Kurol, J. and Bjerklin, K. (1982) Ectopic eruption of maxillary first permanent molars: familial tendencies. *ASDC Journal of Dentistry for Children*, 49, 35–38.
42. Russell, K.A. and McLeod, C.E. (2008) Canine eruption in patients with complete cleft lip and palate. *The Cleft Palate Craniofacial Journal*, 45, 73–80.
43. Westerlund, A., Sjöström, M., Björnström, L. and Ransjö, M. (2014) What factors are associated with impacted canines in cleft patients? *Journal of Oral and Maxillofacial Surgery*, 72, 2109–2114.
44. Campbell, R.E., Levin, L., Mauseth, S.E., Hu, J., Zheng, S., Wilson, S. and Saal, H. (2014) Prevalence of transposed teeth as seen on panoramic radiographs in children with cleft lip and palate. *The Cleft Palate Craniofacial Journal*, 51, e88–e93.
45. Eslami, N., Majidi, M.R., Aliakbarian, M. and Hasanzadeh, N. (2013) Prevalence of dental anomalies in patients with cleft lip and palate. *The Journal of Craniofacial Surgery*, 24, 1695–1698.
46. Cassolato, S.F., Ross, B., Daskalogiannakis, J., Noble, J., Tompson, B. and Paedo, D. (2009) Treatment of dental anomalies in children with complete unilateral cleft lip and palate at SickKids hospital, Toronto. *The Cleft Palate Craniofacial Journal*, 46, 166–172.
47. Kurol, J. (1981) Infraocclusion of primary molars: an epidemiologic and familial study. *Community Dentistry and Oral Epidemiology*, 9, 94–102.
48. Baccetti, T. (1998) A controlled study of associated dental anomalies. *The Angle Orthodontist*, 68, 267–274.
49. Cardoso Silva, C., Maroto Edo, M., Soledad Alvaro Llorente, M. and Barbería Leache, E. (2014) Primary molar infraocclusion: frequency, magnitude, root resorption and premolar agenesis in a Spanish sample. *European Journal of Paediatric Dentistry*, 15, 258–264.
50. Shalish, M., Peck, S., Wasserstein, A. and Peck, L. (2010) Increased occurrence of dental anomalies associated with infraocclusion of deciduous molars. *The Angle Orthodontist*, 80, 440–445.
51. Celebi, A.A., Ucar, F.I., Sekerci, A.E., Caglaroglu, M. and Tan, E. (2015) Effects of cleft lip and palate on the development of permanent upper central incisors: a cone-beam computed tomography study. *European Journal of Orthodontics*, 37, 544–549.
52. Akcam, M.O., Aydemir, H., Özer, L., Özel, B. and Toygar-Memikoğlu, T.U. (2014) Three-dimensional tooth crown size symmetry in cleft lip and cleft palate. *The Angle Orthodontist*, 84, 623–627.
53. Walker, S.C., Mattick, C.R., Hobson, R.S. and Steen, I.N. (2009) Abnormal tooth size and morphology in subjects with cleft lip and/or palate in the north of England. *European Journal of Orthodontics*, 31, 68–75.
54. Rølling, S. and Poulsen, S. (2009) Agenesis of permanent teeth in 8138 Danish schoolchildren: prevalence and intra-oral distribution according to gender. *International Journal of Paediatric Dentistry*, 19, 172–175.
55. Nordgarden, H., Jensen, J.L. and Storhaug, K. (2002) Reported prevalence of congenitally missing teeth in two Norwegian counties. *Community Dental Health*, 19, 258–261.
56. Letra, A., Menezes, R., Granjeiro, J.M. and Vieira, A.R. (2007) Defining subphenotypes for oral clefts based on dental development. *Journal of Dental Research*, 86, 986–991.