

Early identification and management of mandibular canine ectopia

SADJ November 2011, Vol 66 no 10 p462 - p467

APG Hudson: BChD (Stell), HonsBSc (Med Sci) (Stell), MSc (Dent) (UWC), Senior Lecturer, Department of Orthodontics, Faculty of Dentistry, University of the Western Cape.

AMP Harris: BChD (Stell), HonsBSc (Med Sci) (Stell), DiplTerEduc (Unisa), MChD Orthodontics (Stell), FFD(SA) Ortho, PhD (UWC), Professor and Head of Department of Orthodontics, Faculty of Dentistry, University of the Western Cape.

N Mohamed: BChD (Stell), BSc Hons (Paed Dent) (Stell), MSc (Paed Dent), (Stell), Senior Lecturer, Department of Paediatric Dentistry, Faculty of Dentistry, University of the Western Cape.

Corresponding author

APG Hudson: Department of Orthodontics; Faculty of Dentistry; University of the Western Cape; Private Bag X1; Tygerberg, 7505; South Africa;
E-mail: apghudson@uwc.ac.za

ABSTRACT

Mandibular canine impaction and transmigration have serious consequences for the patient, as removal of the tooth or teeth in question is often the only solution. The loss of one or both mandibular canines complicates orthodontic treatment. Early warning signs of mandibular canine ectopia are explored in this paper as well as how to assess the potential for displacement, impaction and/or transmigration. This paper highlights the value of interceptive treatment once the early signs of an aberrant mandibular canine have been detected.

Keywords: Mandibular canine ectopia, impaction, transmigration, translocation

INTRODUCTION

The alignment of the mandibular permanent canine is dependent on the position of the mandibular permanent lateral incisors.¹ As these teeth erupt, they push the primary canines distally and laterally into the primate spaces. This is known as the "secondary spacing phenomenon" as it creates more space in

the arch.^{1,2} During the early mixed dentition stage, minor mandibular incisor crowding of 1 to 1.5mm is normal and is termed 'incisor liability'.¹ It is normal for the permanent canines to erupt labial to the primary canines. This labial eruption leads to an increase in the intercanine distance, which creates more space in the mandibular arch, thereby alleviating this early incisor liability. Therefore, in cases of normal eruption a buccal bulge produced by the mandibular canine should be palpable prior to eruption at any time from the dental age of 9 years. The mandibular teeth normally erupt prior to their maxillary counterparts.³ The most favourable sequence of eruption of the mandibular teeth is 6, 1, 2, 3, 4, 5, 7, 8.⁴ The permanent mandibular canines normally erupt around the dental age of 11 years.⁵ Radiographically, the angle between the mid-sagittal plane and the long axis of a mandibular canine should be between zero and 25 degrees for the eruption of the canines to be considered normal.⁶

Impaction of the mandibular canine is not as common as that of its maxillary counterpart.⁷ In the event of mandibular canines impacting, the prognosis is poor. Between 65% and 90% of impacted mandibular canines are removed.^{8,9} A variety of terms are used to describe aberrant mandibular canines. Ectopic or displaced canines refers to teeth that still have the ability to erupt, albeit out of position. Impacted canines on the other hand refers to those teeth that have lost the ability to erupt because of their position and/or angulation in the mandible. An impacted mandibular canine is considered to be transmigrant when half or more of its length has crossed the mandibular midline.¹⁰

Early diagnosis of canine ectopia is important.¹¹ The interceptive treatment of each and every case depends on the individual characteristics of the case.¹² Both clinical and radiographic interceptive orthodontic investigations should focus on the mandibular canine around the dental age of 9 years, as interceptive treatment options may be considered at this stage of development.¹²

Aetiologically, a number of mixed dentition factors or events, if not intercepted, may lead to ectopia of the mandibular canine with a resulting malocclusion. These factors or events include:

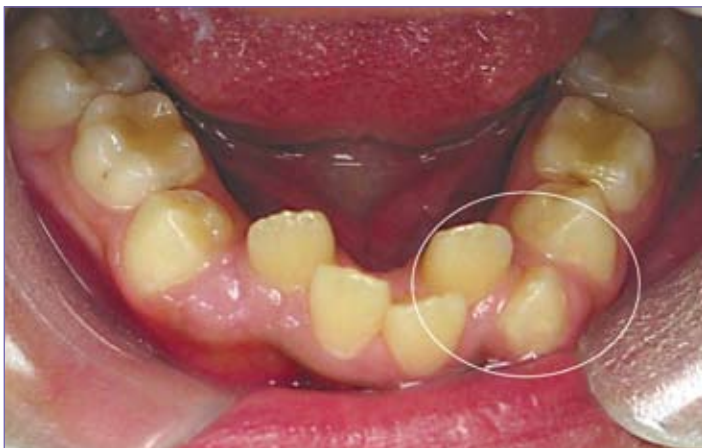

Figure 1: Tooth 33 exhibits mesial drift resulting from the lingually displaced lateral incisor. The unfavourable sequence of eruption on the right side where the first premolar has erupted prior to the mandibular canine should be noted. Untreated, the right side will eventually mirror the left side.

- malposition of the permanent lateral incisors;
- spontaneous early loss of the primary canines;
- abnormal or unfavourable sequence of eruption of the canines and premolars in the mandible;
- anomalies associated with the eruption process.

The purpose of this paper is to explore these early warning signs of mandibular canine ectopia and to assess the potential for displacement, impaction and/or transmigration. This paper also seeks to determine the value of interceptive treatment once the signs of an aberrant mandibular canine have been detected.

MALPOSITION OF THE LATERAL INCISORS

'The permanent mandibular lateral incisor is the most frequently displaced mandibular tooth'.¹³ The aetiology of this displacement is usually associated with an obstruction or crowding. In some cases however, the cause is unknown.¹³ Sayin and Turkkahraman (2004)² found no significant link between mandibular incisor crowding and overall arch length. Incisor crowding is significantly linked to the space available and a diminished transverse dimension of the mandibular arch. This confirms the authors' observation that the secondary spacing phenomenon does not occur in cases where crowding results in the lingual eruption of the permanent mandibular lateral incisors. The malpositioned lateral incisors therefore cannot guide the erupting permanent canines into the correct position. The developing permanent canines erupt in a position more mesial than normal, overlapping the labial aspect of the lateral incisors.¹ Any mesial shift of the posterior teeth together with canine ectopia results in a loss of space (Figure 1).

The first step in the Interceptive management of these cases would be to assess the space needs of the patient. In cases with minor lower incisor crowding, a lower lingual "6 to 6" arch could be placed in order to maintain the leeway space, which could then be utilised to align the incisors and canine(s).^{2,14} Depending on the timing of the lingual arch treatment and the extent of the crowding, it may be considered prudent to extract the primary canines to allow for some self-alignment of the incisors.⁷ More severe cases of crowding should be referred for comprehensive orthodontic treatment.

The only reported transposition pattern in the mandible involves the lateral incisors and canines.¹⁵ Peck *et al.*, (1998)⁹ described the early stage characteristics of transposing mandibular lateral incisors. The teeth exhibit distal tilting and are have a mesiolingual rotation of between 60 degrees and 120 degrees (Figure 2). The resulting lack of contact allows the canine to move mesially. Radiographically, the early stages are characterised by the switched positions of the crowns but not the roots (Figure 3). The transposed lateral incisor frequently precipitates resorption of the first primary molar leading to an early exfoliation. The treatment of this mandibular transposition is dependent on the timing of the diagnosis.¹⁶ If the condition is diagnosed early, i.e. while the permanent canine is still low down in the alveolus, the situation can be intercepted using fixed appliances.¹⁵ Once the permanent canine has erupted, the only practical treatment options that remain are extraction of one of the involved teeth or maintenance of the status quo by accepting the transposition.¹⁵

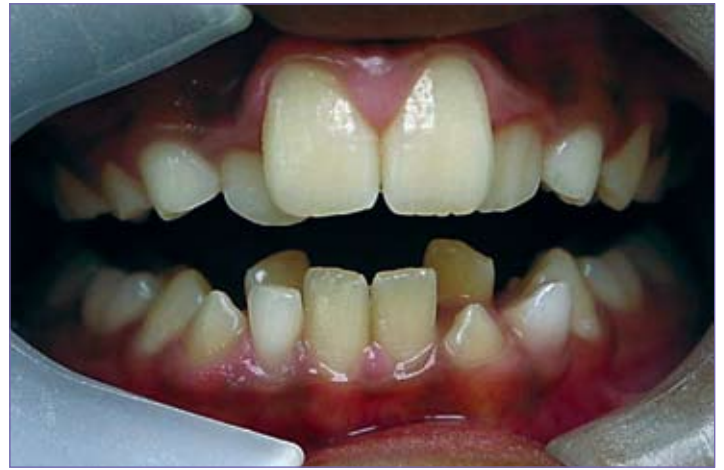

Figure 2: Mesiolingual rotation of tooth 32 and transposition of tooth 33 with the associated retained primary canine. There has been no transposition on the right side.

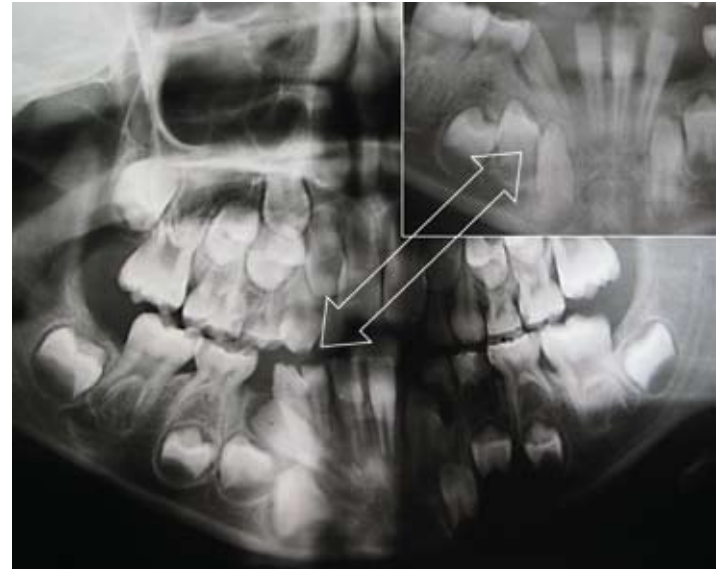


Figure 3: Malposition of the unerupted tooth 42 at dental age of 7 years which caused the early loss of the primary first molar. Interceptively, the 82 and 83 were extracted. The insert shows the same patient 18 months later. Note the uprighting of the 42, the loss of the 74 and the increased splaying of the mandibular incisors with possible loss of leeway space. Space regaining techniques may now be applied to allow incisor alignment.

SPONTANEOUS EARLY LOSS OF THE PRIMARY CANINES

The spontaneous early loss of the primary mandibular canines is an early warning sign of space shortage.¹ This occurs because the erupting mandibular permanent lateral incisors, crowded out of position, exert pressure on the roots of the primary canines, resulting in premature resorption. The mandibular primary canines will therefore exfoliate (at the dental age of 7 years)⁵ prior to the eruption of the maxillary lateral incisors (at the dental age of 8 years).⁵ This early loss may occur unilaterally or bilaterally in the mandible.

Unilateral spontaneous early loss of the primary canine, if left untreated, leads to a shift in the mandibular midline toward that side. The incisors tip toward the space vacated by the lost primary canine, while the posterior teeth may drift mesially. The incisors on the affected side tip lingually as a result of the loss of interproximal contact and under the effect of the mentalis muscle, causing the bite to deepen¹ (Figure 4).

The type of interceptive treatment in these cases depends on whether the intervention is instituted soon after the loss of the primary canine or not.

- If treatment is instituted shortly after the loss, the remaining lower primary canine may be removed, followed by the placement of a lower lingual arch. The aim of this treatment is to maintain the midline relationships as well as to prevent the incisors from collapsing lingually.
- Treatment instituted later, after considerable incisor drift, is more complex, as at that stage the removal of the remaining primary canine will not correct the midline.¹ The incisors have also had more time to collapse lingually. The challenge in these cases is to correct the midline and regain lost space by proclining the collapsed incisors. This will require the use of one of a variety of orthodontic appliances such as the fixed utility arch or a Crozat bihelix appliance.¹⁷

Bilateral spontaneous early loss of the primary canines leads to a bilateral loss of arch perimeter and a deepening of the bite.¹ In this situation, the incisor imbrication is often resolved by the action of the muscles of the lip and tongue which force the lateral incisors distally into the spaces of the primary canine as the incisors tip lingually (Figure 4).

In all cases of bilateral spontaneous loss of the primary canines, the resultant buccal segment crowding will be determined by the sequence of eruption of the permanent canines and premolars, as well as by the degree of space shortage. Should the sequence of eruption be favourable, the canine has a greater chance of good alignment while the second premolar will most likely be blocked out (Figure 5). However, should the first premolar erupt

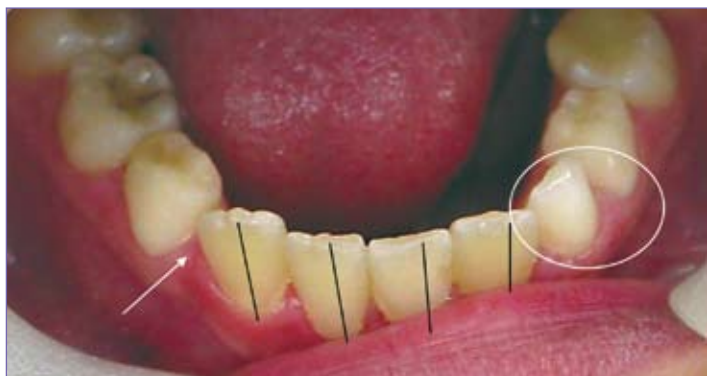

Figure 4: Unilateral early loss of the right primary canine (arrow) showing the resultant inclinations of the incisors and loss of space.

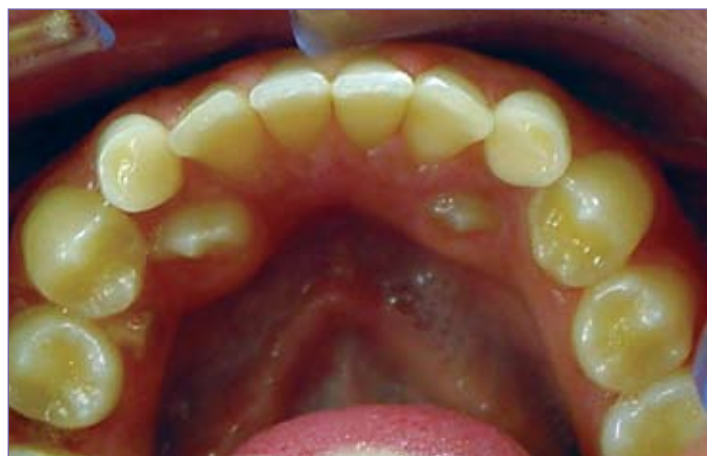

Figure 5: The permanent canines are blocked out of the arch as a result of the unfavourable sequence of eruption of the mandibular teeth and retention of deciduous canines. There is insufficient space in the arch for the permanent canines to self-align. (If the sequence of eruption is favourable, the canines should erupt prior to the premolars and in normal circumstances there would be sufficient space.)

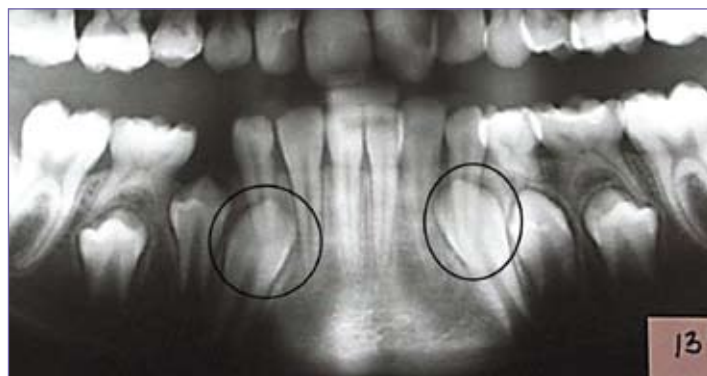

Figure 6: The roots of the primary canines are overlapping the crowns of the permanent canines. The enlarged size of the images of the permanent canines indicates the lingual eruption of those teeth. This anomaly of eruption will allow the first premolars to erupt prior to the permanent canines. The unfavourable sequence of eruption on the right side due to early loss of the first primary molar should be noted.

prior to the canine, the canine will be ectopic. In all these cases it is very important to assess the space situation in order to decide whether the situation can be intercepted or if comprehensive orthodontics is necessary.

Early intervention in cases of early bilateral loss could profitably involve the use of a lingual arch. The later the diagnosis, the more complex the challenge and the more varied the choice of appliances, e.g. a lip bumper, which may be needed to restore the incisor collapse and regain the lost space. It has been suggested that a delay in treatment until the incisors have self-aligned has no detrimental effect,⁷ provided that it is followed by the use of a lingual arch during the mixed dentition. Some form of long-term intervention, such as full-fixed appliances, is important.⁷ Conversely, it is the experience of the authors that it is best to institute interceptive measures as soon as possible after the loss of the primary canine or canines. Any delays tend to complicate the situation.

THE SEQUENCE OF ERUPTION OF THE CANINES AND PREMOLARS IN THE MANDIBLE

An unfavourable sequence of eruption can only be diagnosed radiographically. The consequence of an untreated unfavourable sequence of eruption is that more space than the available leeway space is lost.⁵ Should the first premolar erupt prior to the permanent canine, it is not uncommon for the canine to be buccally or lingually blocked out^{1, 18} (Figure 5). In cases where the primary first molar is lost early, the first premolar often erupts prior to the canine, resulting in crowding (Figure 6). On examination of the panoramic orthopantomogram it is not uncommon for the first premolar to appear to be closer to the occlusal surface than is the developing canine. This, however, does not always mean that the premolar will erupt before the canine. Generally, the tooth with the most root development will be the first to erupt.¹⁹ The resorption patterns of the roots of the primary teeth also play a part in the prediction of the sequence of eruption.¹ Should the roots of the primary canine not be resorbing normally, the sequence of eruption could be altered and result in a blocked-out canine. Where an unfavourable sequence of eruption is suspected, a lingual arch should be fitted in order to secure the leeway space. This would allow the teeth to be aligned once they have erupted, irrespective of the sequence of eruption.

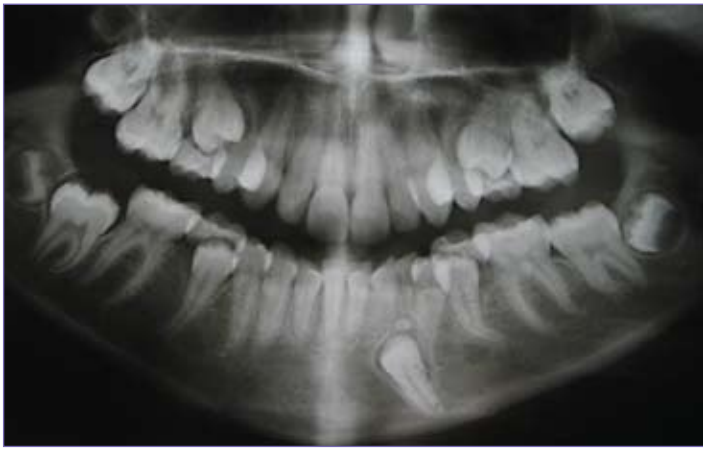

Figure 7: Tooth 33 is blocked out by an odontome and is angled at 36 degrees to the midline. Judging by the advanced stage of root formation, it no longer has the potential to transmigrate.

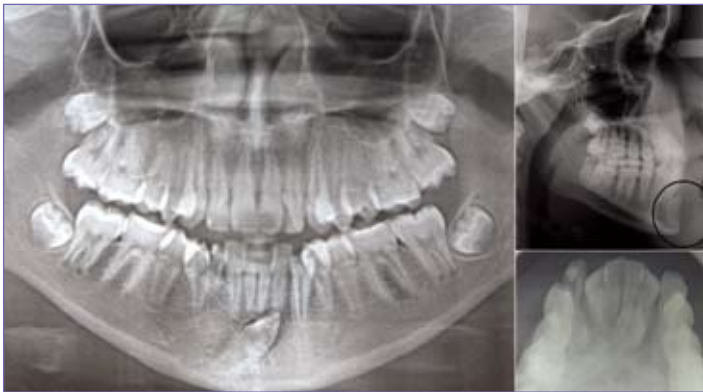


Figure 8: Tooth 43 has crossed the midline. It can be seen lying anterior to the incisor roots in the chin, especially well demonstrated on the lateral cephalometric film.

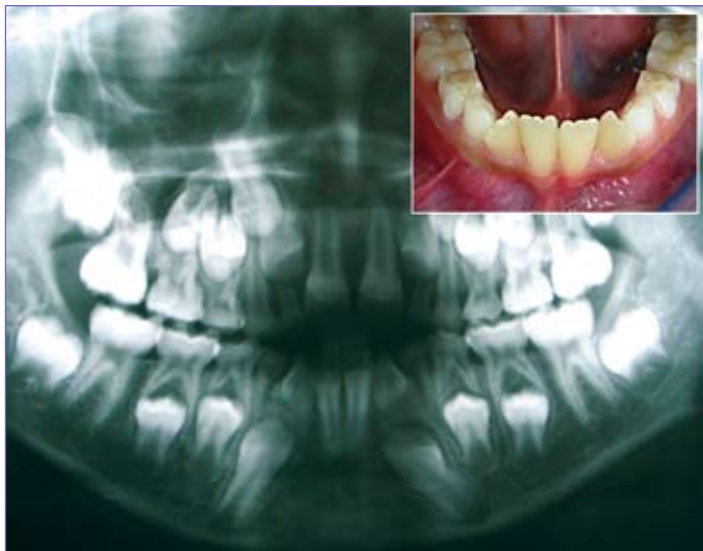

Figure 9: Panoramic radiograph illustrating a patient in the mixed dentition with rotated lateral incisors and canines showing an exaggerated mesial inclination (40 degrees).

ERUPTION ANOMALIES ASSOCIATED WITH THE MANDIBULAR CANINE

Absence of buccal bulges and a lack of mobility of the primary canines around the dental age of 10 years is a strong clinical indication that a developmental anomaly is underway and that there is a very real chance of mandibular canine ectopia and/or impaction.⁶ It is therefore essential for the clinician to perform a radiographic evaluation in each of these cases.¹⁰ An abnormal

position of the follicle of the mandibular canine is accepted as a common cause of mandibular canine ectopia.⁶ It has been suggested that there may be genetic involvement in cases of displacement, as there is an association with hypodontia and palatally-placed maxillary canines²⁰. Odontomas in the canine region are also known to cause transmigration¹⁰ (See Figure 7). Other causes that have been cited are space shortage, premature loss, retention of the deciduous canine, endocrine disturbances, cysts and trauma.²¹

Radiographically, root resorption of the primary canine should normally be seen during the later stages of the development and eruption of the permanent canine. In cases where this root resorption does not take place, the crown of the permanent tooth may be seen to overlap the unresorbed deciduous root (Figure 6). This displacement of the canine will lead to a delay in eruption and may result in an unfavourable sequence with all the associated complications.

As seen on the radiograph, a canine angulation to the midsagittal plane of between 25 degrees and 30 degrees represents a displaced canine. This is, however, not considered to be a predictor that the canine will migrate across the midline. Teeth with an angulation of 30 degrees to 50 degrees are displaced and considered to have the potential to transmigrate. Any canine that displays an angle of more than 50 degrees will definitely cross the midline⁶ (Figure 8). The transmigrating tooth usually travels labial to the roots of the incisors and the crown may go as far as the roots of the first molar on the opposite side.²² The tooth always migrates with the crown leading.⁶ Proclined lower incisors in a patient with a large antero-posterior chin area can allow the canine to move into a horizontal position and transmigrate⁶ (Figure 8). It is uncommon for these teeth to erupt, although they do sometimes appear partially in the mouth after having crossed the midline.²² The greatest amount of tooth migration occurs before root formation is completed. Rapid movement after root formation has however also been observed.⁶ In up to 70% of transmigration cases, the primary canines are retained.¹⁰

Figure 9 shows canines at an angle of 40 degrees to the midline. Interceptive treatment could be implemented by removing the primary canines and placing a lingual arch aligned according to the suggestions made by Joshi (2001).⁶ It is important that any interceptive treatment constantly be monitored for signs of success. In the planning of comprehensive cases where premolar extractions are being contemplated as a treatment option, such extractions should only be done once the migrating canine situation (if it exists) has been taken into account.⁶

CONCLUSION

The non-eruption or ectopic eruption of the mandibular canine leads to a collapse of the mandibular arch with implications for the maxillary arch and for the overall orthodontic treatment of these patients. Early diagnosis and interceptive treatment of the aberrant mandibular canine should be seen as a vital aspect of holistic paediatric dental practice. Monitoring the development of the dentition should be the cornerstone of all paediatric dental care.

It is important to analyse the mixed dentition space situation, as interceptive treatment can only be successful in situations where there is sufficient space. This needs to be combined with a panoramic orthopantomogram at the dental age of 9 years. It is also important to monitor the mobility of the primary canines and to compare the left and right hand sides. The presence of the buccal bulges should be monitored clinically.

Any interceptive treatment that is instituted should be followed up rigorously in order to monitor whether the intended result is being achieved or not.

Declaration: No conflict of interests.

REFERENCES

- Nanda SK. Events in the lifecycle of each permanent tooth. In: The Developmental Basis of Occlusion and Malocclusion. Quintessence Publishing Co Inc, Chicago, 1983, p81-158.
- Sayin M, Turkkahraman H. Factors contributing to mandibular anterior crowding in the early mixed dentition. *Angle Orthod* 2004;**74**:754-8.
- Savara BS, Steen JC. Timing and sequence of eruption of permanent teeth in a longitudinal sample of children from Oregon. *J Am Dent Assoc* 1978;**97**:209-14.
- Moyers RE. Analysis of dentition and occlusion. In: Handbook of Orthodontics. 4th edition. Year Book Medical Publishers Inc, Chicago 1988, p221-45.
- Profit WR. The later stages of development. In: Contemporary Orthodontics. CV Mosby Co, St Louis 1986: p63-94.
- Joshi MR. Transmigrant mandibular canines: A record of 28 cases and a retrospective review of the literature. *Angle Orthod* 2001;**71**:12-22.
- Sayin M, Turkkahraman H. Effects of lower primary canine extraction on the mandibular dentition. *Angle Orthod* 2006;**76**:31-5.
- Yavuz MS, Aras MH, Buyukkurt MC, Tozoglu S. Impacted mandibular canines. *J Contemp Dent Pract* 2007;**8**:78-85.
- Peck S, Peck L, Kataja M. Mandibular lateral incisor-canine transposition, concomitant dental anomalies, and genetic control. *Angle Orthod* 1998;**68**:455-66.
- Gonzalez-Sanchez MA, Berini-Ayres L, Gay-Escoda C. Transmigrant impacted mandibular canines. *J Am Dent Assoc* 2007;**138**:1450-5.
- Stafne EC. Malposed mandibular canine. *Oral Surg Oral Med Oral Pathol* 1963;**16**:1330.
- Lagares DT, Ruiz RF, Cossio PI, Calderon MG, Perez JLG. Transmigration of impacted lower canine. Case report and review of literature. *Med Oral Patol Cir Bucal* 2006;**11**:171-4.
- Shapira Y, Kufteinc M. Intrabony migration of impacted teeth. *Angle Orthod* 2002;**73**:738-43.
- Brennan MM, Gianelly AA. The use of the lingual arch in the mixed dentition to resolve incisor crowding. *Am J Orthod Dentofac Orthop* 2000;**117**:81-5.
- Doruk C, Babacan H, Bicakci A. Correction of a mandibular lateral incisor-canine transposition. *Am J Orthod Dentofac Orthop* 2006;**129**:65-72.
- Shapira Y, Kufteinc MM. Early detection and prevention of mandibular tooth transposition. *J Dent Child (Chic)* 2003;**70**:204-7 (abstract).
- Patti A, Perrier D'Arc G. Appliances. In: Clinical Success in Early Orthodontic treatment. Quintessence books, Paris 2005: p101-18
- Van der Linden PGM, Duterloo HS. The first transitional period. In: Development of the Human Dentition - An atlas. Harper & Row, 1976:p75-142.
- Burdi AR, Moyers RE. Development of the dentition and the occlusion. In: Handbook of Orthodontics. 4th edition. Year Book Medical Publishers Inc, Chicago 1988:99-146.
- Peck S. On the phenomenon of intraosseous migration of non-erupting teeth. *Am J Orthod Dentofacial Orthop* 1998;**113**:515-7.
- Buyukkurt MC, Aras MH, Caglaroglu M, Gungormus M. Transmigrant mandibular canines. *J Oral Maxillofac Surg* 2007;**65**:2025-9.
- Camilleri S, Scerri E. Transmigration of mandibular canines – A review of the literature and a report of five cases. *Angle Orthod* 2003;**73**:753-62.

EOWS201111CMD

NOTICE:

2012 SADA Annual General Meeting



Notice is hereby given that the Annual General Meeting of the South African Dental Association will be held at the **Sunnyside Park Hotel, Parktown, Johannesburg**, on **Thursday 15 March 2012 at 18:00** followed by snacks and refreshments. The Agenda for the meeting will be circulated to members with the Annual Report.

SADA is **your** Association and your voice counts.

Maretha Smit
Chief Executive Officer