

Osteopetrosis complicated by osteomyelitis of the maxilla: A rare case report and review of the literature

Osteopetroza powikłana zapaleniem szpiku szczęki – opis rzadkiego przypadku i przegląd piśmiennictwa

Moegamat Sallies^{A–D,F}, Fadi Titinchi^{A,B,D,F}, Jean Morkel^{A,D–F}

Department of Maxillofacial and Oral Surgery, Faculty of Dentistry and WHO Collaborating Center, University of the Western Cape, Cape Town, South Africa

A – research concept and design; B – collection and/or assembly of data; C – data analysis and interpretation;
D – writing the article; E – critical revision of the article; F – final approval of the article

Dental and Medical Problems, ISSN 1644-387X (print), ISSN 2300-9020 (online)

Dent Med Probl. 2020;57(3):327–332

Address for correspondence

Fadi Titinchi
Email: ftitinchi@uwc.ac.za

Funding sources

None declared

Conflict of interest

None declared

Received on February 16, 2020

Reviewed on March 8, 2020

Accepted on April 1, 2020

Published online on September 30, 2020

Abstract

Osteopetrosis is a rare hereditary bone disorder that results in an increase in bone density due to gene mutations and osteoclastic dysfunction. This may lead to cranial nerve compression, bone fractures and osteomyelitis. Osteomyelitis of the maxilla is rare even in osteopetrosis patients.

We report on a case of a 25-year-old male who presented with multiple episodes of osteomyelitis of the maxilla following dental extractions. The patient was initially managed with the incision and drainage of an acute infection, and intravenous amoxicillin-clavulanic acid. This was followed by the debridement of necrotic bony margins and packing with bismuth iodoforn paraffin paste (BIPP) as well as long-term clindamycin. Once osteomyelitis was clear, the primary closure was achieved with a buccal advancement flap and supported by an acrylic obturator. Challenges in the management are highlighted, including preparing for a surgical intervention a patient with chronic low hemoglobin levels and a lack of healthy bony margins in the maxilla. The literature is also reviewed for similar cases.

Key words: osteomyelitis, maxilla, osteopetrosis

Słowa kluczowe: zapalenie szpiku, szczęki, osteopetroza

Cite as

Sallies M, Titinchi F, Morkel J. Osteopetrosis complicated by osteomyelitis of the maxilla: A rare case report and review of the literature. *Dent Med Probl.* 2020;57(3):327–332. doi:10.17219/dmp/119998

DOI

10.17219/dmp/119998

Copyright

© 2020 by Wrocław Medical University

This is an article distributed under the terms of the

Creative Commons Attribution 3.0 Unported License (CC BY 3.0)

(<https://creativecommons.org/licenses/by/3.0/>).

Introduction

Osteopetrosis is a rare hereditary bone disorder that results in an increase in bone density due to gene mutations and osteoclastic dysfunction. The disorder is classically divided into 3 types with variable clinical features. The dominant form of osteopetrosis is typically seen in adults with a late onset whereas the 2 recessive forms of osteopetrosis are typically observed in children with an early onset and a high mortality rate. As bone expansion occurs, marrow spaces become obliterated, which results in fractures, poor wound healing and an increased risk of infections, such as osteomyelitis. Osteomyelitis of the maxilla is relatively rare owing to rich collateral blood supply and thin cortical bone. The diagnosis is established with a thorough history, and physical and radiographic examinations, with the latter being the mainstay. Treatment principles involve managing the identified complications. In the case of osteomyelitis, conservative and preventative care principles play a significant role in the management of patients with osteopetrosis. It is vital that patients with osteopetrosis are made aware of good oral hygiene and dental care practices so as to avoid the need for further treatment. Carious teeth should thus initially be treated with restorations or the endodontic therapy with the aim of preventing tooth extractions and the subsequent surgical complications, such as osteomyelitis. If conservative and preventative measures are compromised, and patients with osteopetrosis develop osteomyelitis, the debridement of necrotic tissue with an adjunctive antibiotic therapy is mandated.¹

Case report

A 25-year-old male patient was referred to the Department of Maxillofacial and Oral Surgery at the University of the Western Cape, Tygerberg Hospital in Cape Town, South Africa, with chronic infections and recurrent swelling. The patient reported that the infective process had started 6 months ago, after the extraction of the upper right molar, and had exacerbated 1 day prior to presentation at the clinic.

Past medical history revealed that the patient sustained multiple bone fractures throughout his life, such as forearm and ankle fractures. Upon proceeding with a detailed history, and physical and radiographic examinations, the diagnosis of osteopetrosis with underlying osteomyelitis was confirmed. The patient was not on any chronic medications and had not been on antiresorptive/antiangiogenic agents previously.

Clinically, the patient presented with soft, tender, right facial swelling associated with the right canine space region and the upper lip. Intraorally, the mandible

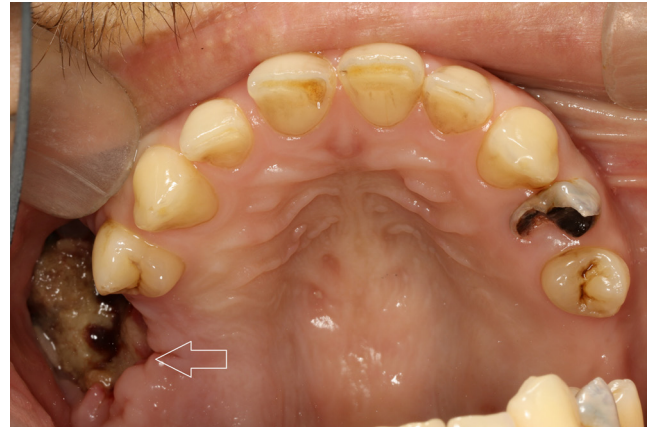


Fig. 1. Intraoral image showing the osteomyelitis of the right maxilla following a dental extraction

appeared edentulous and pus discharge was found in the right maxillary region with a draining fistula associated with the right first molar area (Fig. 1). A radiographic examination demonstrated increased bone opacity, poorly pneumatized paranasal sinuses and multiple unerupted teeth (Fig. 2). Additionally, cone-beam computed tomography (CBCT) further illustrated increased bone opacity with poor differentiation between medullary and cortical bone (Fig. 3).

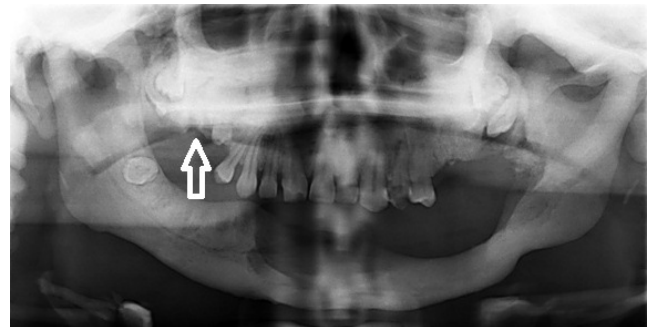

Fig. 2. Pantomograph of the patient showing opacity in the maxilla and multiple unerupted teeth (note the previous marginal resection of the left mandible)

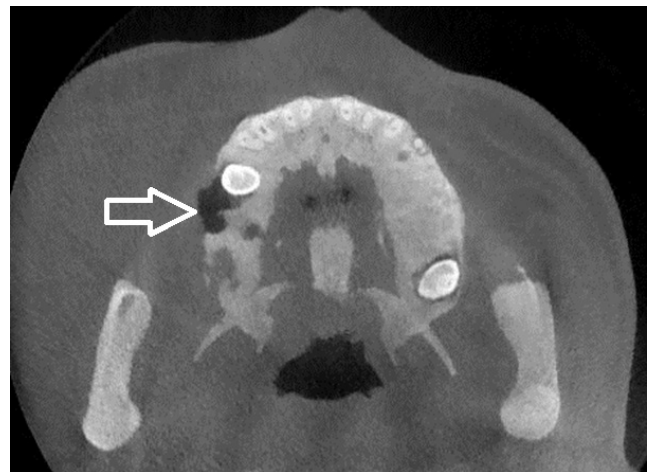

Fig. 3. Axial cone-beam computed tomography (CBCT) scan showing right-sided osteomyelitis in the maxilla

With regard to the management of the patient at this point, the retained root of a maxillary first molar was surgically removed, incision and drainage were performed, a pus swab was taken, and augmentin IV was administered for 7 days. Following this initial intervention, swelling decreased and the patient reported the alleviation of pain.

Three weeks following discharge, the patient returned, complaining of severe pain and tenderness associated with the same area. An intraoral examination revealed pus discharge from a non-healing maxillary first molar socket with areas of exposed bone. The region was then debrided and packed with bismuth iodoform paraffin paste (BIPP) gauze, the canine space was explored and irrigated, and biopsy was performed. Thereafter, the patient was admitted for 7 days for monitoring and irrigation, with an adjunctive antibiotic therapy in the form of 1.2 g of augmentin, administered intravenously (i.v.) every 8 h pending microscopy, culture and sensitivity testing. At day 3 of admission, the patient was switched to 600 mg of clindamycin i.v. every 6 h, as the cultured bacteria were resistant to penicillin. Hematological studies revealed reductions in the red blood cell count ($2.78 \times 10^{12}/L$), hemoglobin (6.8 g/dL) and platelet count ($146 \times 10^9/L$) with the C-reactive protein level markedly elevated (83 mg/L). Additionally, the iron level was at the lower limit of the normal range, requiring the prescription of ferric sulfate. The histological examination of the obtained biopsy showed strips of acanthotic, stratified squamous oral mucosa with dense submucosal chronic inflammation (Fig. 4). Fragments of non-vital bone with the surrounding cellular debris, hemorrhage and basophilic bacterial colonization were noted, which was indicative of a sequestrum.

Following that, the patient required 2 additional debridements under general anesthesia with blood transfusions due to chronic low hemoglobin. The patient was also prescribed pentoxifylline and tocopherol orally to aid in bone healing. The wound was then closed, primarily with a buccal advancement flap, and an acrylic obturator was used to support the wound.

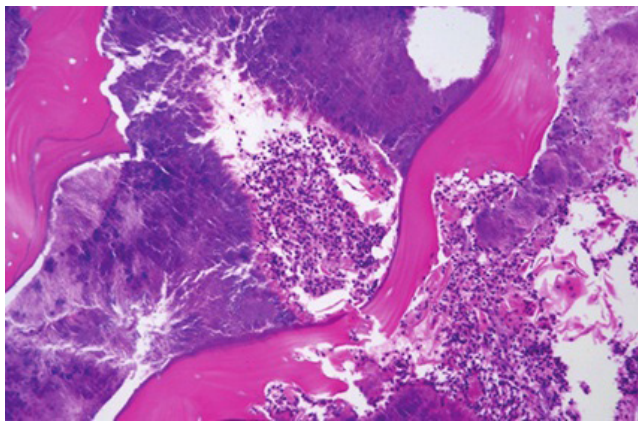


Fig. 4. Hematoxylin and eosin (H&E)-stained slide showing the signs of suppurative osteomyelitis with inflammatory infiltrate and necrotic bone

Discussion

Multiple genetic mutations are responsible for the presentation of osteopetrosis.² The mutated genes of significance include *CLCN7* and *TGIRG1*, which results in the functional defects of the enzyme carbonic anhydrase II.² Osteoclasts ultimately cannot form ruffled borders, causing defective bone resorption with the subsequent accumulation of bone, thereby increasing bone density and the fracture risk.²

Osteopetrosis is classified into 3 clinical categories, namely benign autosomal dominant, severe malignant autosomal recessive and intermediate mild autosomal recessive. The dominant form of the disorder is more common in adults. In contrast, the rarer autosomal recessive types are typically associated with an early onset and poor prognosis.²

Bones in patients with osteopetrosis are poorly vascularized. This adversely affects the healing process and results in a marked increase in infection susceptibility.³ As bone becomes denser, its marrow cavities and the pulpal chambers of the teeth become obliterated with the resultant constriction of the neurovascular bundles supplying the jaws and the teeth.³ The extension of bone into the cranial nerve foramina and marrow cavities may compromise both hematologic and neurological functions.⁴ Hematological compromises include frequent infections, profound anemia and hepatosplenomegaly,⁴ as in the case of our patient. Neurological compromises may result in nerve palsies, deafness and blindness.⁴ Additionally, dental caries and bone necrosis may also develop as a consequence of bone expansion, which ultimately results in osteomyelitis.⁵ Osteomyelitis is thus a well-known complication associated with osteopetrosis due to its hypovascular nature.¹ This infection commonly presents in the mandible post-extraction or after the surgical exposure of bone, warranting adequate infection control practices before and after dental surgical procedures.¹

In the dental setting, patients with osteopetrosis present with complications such as dental caries, premature tooth loss, delayed eruption of teeth, enamel hypoplasia, tooth crown and root malformations, and thickened lamina dura.⁵

The diagnosis of osteopetrosis is based on both clinical and radiographic findings, with the latter being the mainstay.⁵ A radiographic examination reveals diffuse osteosclerosis, involving the spine, the skull, the pelvis, and appendicular bones. Additionally, cortical thickening with the resultant medullary encroachment can be visualised.⁶ Differential diagnoses that are to be considered include metaphyseal dysplasia, pyknodysostosis, diaphyseal sclerosis, osteopathia striata, osteopoikilosis, melorheostosis, Camurati–Engelmann disease, and infantile cortical sclerosis.⁵

Table 1. Summary of 24 reported cases of osteomyelitis of the maxilla in patients with osteopetrosis

Study	Patient's age	Patient's gender	Clinical signs	Radiographic signs	Management
Celakil et al. 2016 ³	48	male	purulent discharge from the maxilla	extensive bone defects of the maxilla and the mandible	– dental extractions – sequestrectomy – use of a denture as an obturator
de Azambuja Carvalho et al. 2018 ⁹	40	male	pain and swelling of the left buccal, periorbital and temporal regions, a fistula in the left maxillary region	CT scan showing temporoparietal and maxillary swelling	surgical management: – incision and drainage – sequestrectomy – partial resection of the left maxilla and the zygomatic bone – treatment with hyperbaric oxygen post-operative antibiotics: – ciprofloxacin for 6 months – clindamycin for 6 months
Pavan et al. 2018 ¹⁰	13	male	diffuse, erythematous, tender swelling of the right maxillary and zygomatic regions, a slight mobility of the right maxillary molars with a discharging sinus	increased bone density, the obliteration of the frontal and maxillary sinuses	The extractions of necessary teeth and the sinus tract excision were recommended, but the patient's parents refused surgical interventions. The patient was managed with systemic antibiotics and blood transfusions due to the resultant anemia.
Kulyapina et al. 2016 ¹¹	66	male	oroantral fistula, a non-healing socket of a third molar with areas of exposed bone, hearing impairment	area of bone destruction and sequestrum formation in the right maxilla	initial management: – systemic antibiotics for 1 month surgical management: – closure of the oroantral fistula – sequestrectomy
Mikami et al. 2016 ¹²	54	male	pain and swelling of the right facial region, trismus	radiolucent areas associated with the maxillary and mandibular molars	– dental extractions – sequestrectomy – cephazolin – clindamycin
de Carvalhosa et al. 2016 ¹³	6	female	avulsion of 2 maxillary central incisors, resulting in a non-healing wound, exposed necrotic bone in the anterior maxilla	intense opacity of the cortical bone of the maxilla and the periorbital region	– extractions of unerupted maxillary teeth – sequestrectomy
Infante-Cossio et al. 2014 ¹⁴	40	female	cutaneous fistula with purulent discharge from the bilateral submandibular and right infraorbital regions, exposed necrotic bone, blindness due to optic nerve compression	diffuse opacity of the maxillary and mandibular bone, multiple impacted teeth	initial management: – amoxicillin/clavulanic acid for 1 month surgical management: – local debridement
Adachi et al. 2013 ¹⁵	44	female	fistula with purulent discharge in the left maxillary buccal region	generalized sclerosis of the maxilla and the mandible, the obliteration of the maxillary sinuses	initial management: – cefazolin for 7 days. surgical management: – sequestrectomy
Arunkumar et al. 2011 ¹⁶	54	male	chronic discharge, swelling and an ulcer over the left cheek, a discharging sinus tract inferior to the left outer canthus, oroantral fistula	destruction of the alveolar process in the 2 nd quadrant and the left zygomatic arch	– ofloxacin – extractions of involved teeth – excision of the fistula – sequestrectomy
Balan et al. 2011 ¹⁷	8	male	painful left-sided facial swelling with purulent discharge from a carious primary molar	increased bone density, diffuse sclerosis, multiple unerupted teeth	– systemic antibiotics – local debridement of the maxilla
Khademi et al. 2011 ¹⁸	15	male	bilateral facial pain and swelling with infraorbital sinus tract drainage, vision and hearing problems	obliteration of the maxillary sinuses, sequestration of the maxilla and the zygomatic bone	initial management: – clindamycin surgical management: – curettage – sequestrectomy – sinus tract excision
Ambika et al. 2010 ¹⁹	28	male	non-healing extraction socket with exposed necrotic bone in the right molar region associated with painful, extraorally draining facial swelling	increased bone density, erosion of the buccal cortices of the right maxilla, the zygomatic bone, the lateral orbital wall, and the maxillary sinus	– ciprofloxacin – local debridement – sequestrectomy Partial maxillectomy was planned, but the patient refused treatment.
Oğütçen-Toller et al. 2010 ²⁰	18	female	purulent discharge from the infraorbital and left maxillary molar regions, partial edentulism with multiple malformed teeth, blindness	diffuse hyperdensity of the maxilla and the mandible, sequestrum formation, multiple impacted teeth	initial management: – amoxicillin for 7 days surgical management: – extractions of all partially impacted and malformed teeth – sequestrectomy post-operative antibiotics: – sultamicillin and ornidazole for 5 weeks – treatment was altered to clindamycin for 1 week, sultamicillin and ornidazole for 3 weeks followed by cefuroxime axetil for 4 weeks

Continued Table 1

Study	Patient's age	Patient's gender	Clinical signs	Radiographic signs	Management
Krithika et al. 2009 ²¹	18	male	purulent discharge bilaterally from buccal mucosa, yellow-white exposed bone appearing bilaterally in the maxilla at non-healing molar extraction sites, vision and hearing impairment	increased bone density with the diffuse sclerosis of the maxillary and zygomatic bones	initial management: – blood transfusion to address anemia – augmentin surgical management: – corticotomy
Krithika et al. 2009 ²¹	16	male	infraorbital, cutaneous pus-draining sinus following a dental extraction, generalized enamel hypoplasia, multiple missing permanent teeth	generalized sclerosis of bones with an increase in bone density, the obliteration of the maxillary and paranasal sinuses	initial management: – blood transfusion to address anemia – levofloxacin for 1 week surgical management: – sequestrectomy
Trivellato et al. 2009 ²²	25	male	recent extraction socket with right maxillary and mandibular bone exposure with associated cutaneous draining fistulas	increased bone density, multiple edentulous areas	initial management: – clindamycin surgical management: – marginal resection of the right maxilla and mandible – partial resection of the mandible after recurrence
Vázquez et al. 2009 ²³	23	female	infection of the right posterior maxilla and anterior mandible with an associated fistula	marked increase in bone opacity, periapical radiolucency associated with the mandibular teeth	– dental extractions – curettage of sockets – penicillin IV for 3 weeks
Barry et al. 2007 ²⁴	28	female	oroantral fistula, poorly healed extraction socket with areas of visible sequestration, mucopurulent discharge from middle meati	osteosclerosis, moth-eaten appearance, the bone destruction of the maxillary sinus, the hard palate and the left nasal cavity	conservative management: – metranidazole – cefuroxime – 0.1% betamethasone sodium phosphate nasal drops
Barry et al. 2007 ²⁴	27	female	severe halitosis with chronic nasal discharge, oroantral fistula with purulent discharge	increased bone density	– amoxicillin/clavulanic acid – local debridement – antral wash – closure of the oroantral fistula with a buccal advancement flap
Junquera et al. 2005 ²⁵	60	female	poorly healed extraction sockets with sequestrum formation in the 2 nd quadrant	bone destruction with visible sequestration	initial management: – amoxicillin/clavulanic acid for 1 month surgical management: – sequestrectomy
Fernandez et al. 2003 ²⁶	9	female	painful, erythematous swelling of the left maxillary region with purulent discharge from the cutaneous sinus tract, unerupted maxillary teeth, vision problems	increased bone density, radiolucency associated with first and second molars, multiple unerupted and malformed permanent teeth	initial management: – clindamycin – blood transfusion to address anemia surgical management: – curettage – local debridement
Long et al. 2001 ²⁷	54	male	palatal swelling, an oroantral fistula, multiple draining fistulas of the maxilla	reduced marrow spaces, areas of necrotic maxillary bone	– systemic antibiotics – extractions of remaining maxillary teeth – local debridement – sequestrectomy
Crockett et al. 1986 ²⁸	24	female	diffuse swelling of the left middle and lower thirds of the face with a draining sinus tract, soft green-colored exposed bone in the 2 nd quadrant	increased bone density, generalized sclerosis of bone, bone destruction of the left maxilla, the antrum and the zygomatic bone	initial management: – cefoxitin IV surgical management: – removal of polypoid nasal tissue – sequestrectomy – left partial maxillectomy rehabilitation: – upper denture with an obturator to close the surgical defect
Sofferan et al. 1971 ²⁹	27	female	exposed necrotic anterior maxillary alveolar bone with halitosis and purulent nasal discharge following the extractions of the maxillary teeth, total blindness of the right eye	obliteration of the maxillary sinuses, sequestration of the left maxilla	– local debridement – sequestrectomy – drains placed from the maxillary sinuses through nasal antrostomies – construction of a maxillary prosthesis

CT – computed tomography.

If patients start exhibiting such symptoms as fractures, sepsis, or hematological or neurological abnormalities, medical consultation and management may be necessary.⁷ Management principles aim to modulate and stimulate osteoclastic activity.⁵ Attempts at stimulating osteoclastic activity have been made previously, all with variable success rates, such as utilizing the calcitriol therapy, the regulation of calcium, steroids, and parathyroid hormone.⁵ Palliative treatment involves the debridement of grossly necrotic bone and nerve decompression.⁵ Hemopoietic stem cell transplantation has been proven to be a useful modality to improve the survival rate of patients with the autosomal recessive variants of osteopetrosis.⁷


Treatment modalities that are utilized for osteomyelitis in the jaws secondary to osteopetrosis include incision and drainage, dental extractions, an antibiotic therapy, sequestrectomy, saucerization, decortication, jaw resections, and hyperbaric oxygen.⁸ Obturators are ideally used to close defects; free bone grafts are not recommended due to the compromised blood supply to the graft bed.⁸


No definitive treatment protocol currently exists for osteopetrosis, as shown in Table 1.^{3,9–29}

In conclusion, from our experience in the management of this patient and the reviewed literature, patients with osteopetrosis complicated by osteomyelitis of the maxilla should be treated with a long-term antibiotic therapy (amoxicillin/clavulanic acid and/or clindamycin), accompanied with the surgical debridement/sequestrectomy and packing the site with a medicament (BIPP or Whitehead's varnish) to aid in healing and to prevent further infections. Regular long-term follow-up is vital to assess healing and prevent the dissemination of the disease process.

ORCID iDs

Moegamat Sallies  <https://orcid.org/0000-0003-1878-8572>

Fadi Titinchi  <https://orcid.org/0000-0003-3182-7038>

Jean Morkel  <https://orcid.org/0000-0001-9338-6712>

References

- Patil K, Mahima VG, Raina A, Mutneja P. Osteopetrosis: A case report. *Int J Med Dent Case Reports*. 2016;3:1–3.
- Jayachandran S, Preethi M. Clinical spectrum of osteopetrosis with secondary osteomyelitis of the mandible: Report of two cases. *J Indian Acad Oral Med Radiol*. 2018;30(2):165–168.
- Celakil T, Dogan M, Rohlig BG, Evlioglu G, Keskin H. Oral rehabilitation of an osteopetrosis patient with osteomyelitis. *Case Rep Dent*. 2016;2016:6930567.
- Wu CC, Econs MJ, DiMeglio LA, et al. Diagnosis and management of osteopetrosis: Consensus guidelines from the Osteopetrosis Working Group. *J Clin Endocrinol Metab*. 2017;102(9):3111–3123.
- García CM, García MAP, García RG, Gil FM. Osteomyelitis of the mandible in a patient with osteopetrosis. Case report and review of the literature. *J Maxillofac Oral Surg*. 2013;12(1):94–99.
- Yadav S, Chalise S, Chaudhary S, Shah GS, Gupta MK, Mishra OP. Osteopetrosis in two siblings: Two case reports. *BMC Res Notes*. 2016;9:55.
- Povoroznyuk VV, Dedukh N, Bystrytska M, Musiienko AS. Osteopetrosis: Classification, pathomorphology, genetic disorders, clinical manifestations (literature review and clinical case report). *Pain Joints Spine*. 2019;9(2):135–142.
- Barry CP, Ryan CD. Osteomyelitis of the maxilla secondary to osteopetrosis: Report of a case. *Oral Surg Oral Med Oral Pathol Oral Radiol Endod*. 2003;95(1):12–15.
- de Azambuja Carvalho PH, Moura LB, Gabrielli MFR, Gabrielli MAC, Filho VAP. Maxillary osteomyelitis associated with osteopetrosis: Systematic review. *J Craniomaxillofac Surg*. 2018;46(11):1905–1910.
- Pavan BVNKJ, Kejriwal GS, Kumar BL. Maxillary osteomyelitis in Albers-Schönberg disease: A rare presentation. *JNTR Univ Health Sci*. 2018;7(3):236–239.
- Kulyapina A, Verdaguer Martin J, Navarro Cuellar C, Navarro Vila C. Long-term follow-up of bimaxillary osteomyelitis associated with autosomal dominant osteopetrosis: A case report. *J Maxillofac Oral Surg*. 2016;15:121–126.
- Mikami T, Miake Y, Bologna-Molina R, Takeda Y. Ultrastructural analyses of alveolar bone in a patient with osteomyelitis secondary to osteopetrosis: A review of the literature. *J Oral Maxillofac Surg*. 2016;74(8):1584–1595.
- de Carvalhosa AA, Marinho KCT, de Souza Castro PH, Borges ÁH, Volpato LER, Giovani ÉM. Osteomyelitis of the maxilla in a patient with malignant infantile osteopetrosis. *Rev Esp Cirug Oral y Maxilofac*. 2016;38(2):96–100.
- Infante-Cossio P, Gonzalez-Perez LM, Martinez-de-Fuentes R, Infante-Cossio M, Castaño-Seiquer A, Jimenez-Castellanos E. Maxillomandibular osteomyelitis associated with osteopetrosis. *J Craniofac Surg*. 2014;25(1):e79–e82.
- Adachi M, Iwai T, Watanuki K, Masuda G, Tohnai I. Osteomyelitis of the jaws associated with osteopetrosis: Case report of two sisters. *Oral Surg*. 2013;6(2):73–76.
- Arunkumar JS, Naik AS, Prasad KC, Santhosh SG. Role of nasal endoscopy in chronic osteomyelitis of maxilla and zygoma: A case report. *Case Rep Med*. 2011;2011:802964.
- Balan A, Girija KL, Ranimo P. Osteomyelitis of maxilla in infantile osteopetrosis: A case report with review of literature. *Int J Clin Pediatr Dent*. 2011;4(2):125–128.
- Khademi B, Asefi V, Tarzi M. Osteopetrosis complicated by maxillary osteomyelitis: A case report. *Iran J Otorhinolaryngol*. 2011;23(64):103–107.
- Ambika G, Shikha K, Premdeep G, Virendra S. Maxillary osteomyelitis secondary to osteopetrosis – a rare case report. *J Clin Diagn Res*. 2010;4(5):3261–3265.
- Oğütçen-Toller M, Tek M, Sener I, Bereket C, Inal S, Ozden B. Intractable bimaxillary osteomyelitis in osteopetrosis: Review of the literature and current therapy. *J Oral Maxillofac Surg*. 2010;68(1):167–175.
- Krithika C, Neelakandan RS, Sivapathasundaram B, Koteeswaran D, Rajaram PC, Shetkar GS. Osteopetrosis-associated osteomyelitis of the jaws: A report of 4 cases. *Oral Surg Oral Med Oral Pathol Oral Radiol Endod*. 2009;108(3):e56–e65.
- Trivellato AE, Ribeiro MC, Sverzut CE, Bonucci E, Nanci A, de Oliveira PT. Osteopetrosis complicated by osteomyelitis of the maxilla and mandible: Light and electron microscopic findings. *Head Neck Pathol*. 2009;3(4):320–326.
- Vázquez E, López-Arcas JM, Navarro I, Pingarrón L, Cebrián JL. Maxillomandibular osteomyelitis in osteopetrosis. Report of a case and review of the literature. *Oral Maxillofac Surg*. 2009;13(2):105–108.
- Barry CP, Ryan CD, Stassen LFA. Osteomyelitis of the maxilla secondary to osteopetrosis: A report of 2 cases in sisters. *J Oral Maxillofac Surg*. 2007;65(1):144–147.
- Junquera L, Rodríguez-Recio C, Villarreal P, García-Consuegra L. Autosomal dominant osteopetrosis and maxillomandibular osteomyelitis. *Am J Otolaryngol*. 2005;26(4):275–278.
- Fernandez JMT, Frias MAN, Hernandez SPD. Infantile osteopetrosis: A case report with osteomyelitis of the maxilla. *J Clin Pediatr Dent*. 2003;27(1):77–80.
- Long RG, Ziccardi VB, Lejeune C. Osteopetrosis of the maxilla. *Oral Surg Oral Med Oral Pathol Oral Radiol Endod*. 2001;91(2):139–140.
- Crockett DM, Stanley RB, Lubka R. Osteomyelitis of the maxilla in a patient with osteopetrosis (Albers-Schönberg disease). *Otolaryngol Head Neck Surg*. 1986;95(1):117–121.
- Sofferman RA, Smith RO, English GM. Albers-Schönberg's disease (osteopetrosis). A case with osteomyelitis of the maxilla. *Laryngoscope*. 1971;81(1):36–46.