

Available online at www.sciencedirect.com

journal homepage: www.elsevier.com/locate/radcr

Case report

MACRODONTIA: A brief overview and a case report of KBG syndrome ☆☆☆★☆☆†

Manogari Chetty, BChD, BSc, MChD, PhD, Khaled Beshtawi, BDS, MSc, Imaan Roomaney, BChD, MPH, Salma Kabbashi, BDS, MSc*

Craniofacial Biology, University of the Western Cape, Private Bag X17, Tygerberg 7505, Cape Town, South Africa

ARTICLE INFO

Article history:

Received 22 February 2021

Accepted 27 February 2021

Keywords:

Macrodonia

Dental

Genetic

Malformation

KBG syndrome

ABSTRACT

Macrodonia is a dental condition where a tooth or group of teeth are abnormally larger than average. Functional and aesthetic discrepancies may arise in affected individuals resulting in lowering the quality of life. It has been noted that macrodonia is associated with several genetic and endocrine abnormalities. Among which, KBG syndrome is a rare genetic disorder characterized by developmental and dental abnormalities. This case report provides a brief overview of the significance of macrodonia, along with presenting a case of KBG syndrome with atypical features in a South African, 16-year-old female. The dental manifestations are often overshadowed by other more conspicuous and complex syndromic features. Recognition of both the clinical and oral changes that occur in KBG syndrome facilitates accurate diagnosis and appropriate management of this condition. The authors highlight the importance for clinicians to be cognizant of the clinical implications of macrodonia.

© 2021 The Authors. Published by Elsevier Inc. on behalf of University of Washington.

This is an open access article under the CC BY-NC-ND license

(<http://creativecommons.org/licenses/by-nc-nd/4.0/>)

Introduction

Macrodonia is a term used when teeth that are physically larger than what is considered normal is present [1]. It is thought to affect between 0.03% to 1.9% of people worldwide

[2]. A tooth, or teeth that is greater than two standard deviations larger than the average for their age and gender is considered to be macrodonic [3]. True generalized macrodonia is rare and seen infrequently in conditions such as pituitary gigantism [4]. The localized phenotype involving just one or a few teeth is even more rare [4]. Macrodonia is far less com-

☆ Acknowledgments: The authors would thank Dr. Warren Farao and Mr. Clayton Johnson for their assistance.

☆☆ Competing interests: They have no conflict of interest or benefits of any form received from a commercial party related directly or indirectly to the subject of this article.

* Patient consent: Informed consent to publish clinical information and pictures was obtained from the affected persons, with a signature from a health professional as a witness.

** All investigations were undertaken with full ethical approval in accordance with the Declaration of Helsinki as updated in the version promulgated in June 2013 and the Singapore Statement on Research Integrity.

† The content of this article is the sole work of the authors. No benefits of any form have been or are to be received from a commercial party related directly or indirectly to the subject of this article.

* Corresponding author.

E-mail address: 3619347@myuwc.ac.za (S. Kabbashi).

<https://doi.org/10.1016/j.radcr.2021.02.068>

1930-0433/© 2021 The Authors. Published by Elsevier Inc. on behalf of University of Washington. This is an open access article under the CC BY-NC-ND license (<http://creativecommons.org/licenses/by-nc-nd/4.0/>)

mon than microdontia and occasionally the term “megadontia” may be used for this condition [5].

Macrodontia can be classified as:

- (i) True generalized macrodontia where all teeth are larger than normal. The condition is extremely rare and most often seen in cases of pituitary gigantism [1].
- (ii) Relative generalized macrodontia, where teeth might be normal or only slightly larger in size but erupts in small jaws. This condition is also called pseudo-macrodontia and can happen when a child inherits jaw size from one parent and tooth size from the other [4].
- (iii) Macrodontia of a single tooth, which involves a normal tooth in every aspect, aside from size. It is a highly unusual variant when an isolated tooth displaying macrodontia resulting from gemination or fusion of two teeth [4].

Aetiology

Several aetiological factors have been associated with macrodontia, including genetic, environmental, and endocrine abnormalities [6]. It has been reported that macrodontia occurs more frequently in people of Asian descent, Native Americans and Alaskans [2,7]. Moreover, males are more likely than females to develop macrodontia [4].

Macrodontia is associated with endocrine abnormalities. Acromegaly and pituitary gigantism are two rare conditions resulting from excessive secretion of growth hormone (GH), usually as a result of pituitary adenoma formation [8]. Pituitary gigantism occurs when there is excessive GH secretion and/or high levels of its mediator, Insulin-like growth factor-1 which overlaps with the period of rapid linear growth during childhood and adolescence [8,9]. Over the past two decades, our increasing understanding of the molecular and genetic aetiologies of pituitary gigantism and acromegaly yielded several genetic causes, including multiple endocrine neoplasia type 1 and 4, McCune-Albright syndrome, Carney complex, familial isolated pituitary adenoma, pituitary adenoma association due to defects in familial succinate dehydrogenase genes, and the recently identified X-linked acrogigantism [9]. Generally, pituitary gigantism is a sporadic and isolated condition. However, it may occur within the context of a coexisting disorder or arise according to a pattern of familial inheritance [10]. Syndromes in which gigantism is a well-recognized feature include McCune-Albright syndrome; multiple endocrine neoplasia type 1; multiple endocrine neoplasia type 4; Carney complex; and the paraganglioma, pheochromocytoma, and pituitary adenoma association known as 3PA [9,10]. GH excess has also been observed in the setting of neurofibromatosis and optic nerve tumors. The frequency of gigantism is established in only a subset of these conditions and varies significantly [9].

According to researchers, variations in genes which regulate tooth growth could cause teeth to grow together. These variations can also cause the teeth to continue to grow beyond what is considered normal. This results in larger than normal teeth [11]. Genetic conditions in which macrodontia often occurs is listed in Table 1.

Molecular basis of macrodontia

Odontogenesis is a complex process involving genes, growth factors, transcription factors as well as signaling pathways to ensure normal tooth formation [12]. Any mutation in these genes and any disruption of the regulatory molecules could result in a dental anomaly [13].

Odontogenesis is under the control of homeobox genes, referred to as HOX genes, together with regulatory mesenchymal molecules and their respective receptors. The HOX gene family is composed of sonic hedgehog, orthodontical, gooseoid, muscle segment (*Msx1* and *Msx2*), distal-less (*Dlx*) and paired box gene 9 (*Pax9*) [13]. The position, development and maturation of tooth buds is regulated by *Msx1* and *Msx2* genes respectively. While, the development of molar teeth is controlled by *Dlx1*, *Dlx2*, and *Barx1* genes [14,15].

The transcription factor, *Pax9*, is required for tooth morphogenesis and instituting the inductive capacity of the tooth mesenchyme which is essential for the mesenchymal expression of bone morphogenetic protein (*Bmp4*), *Msx1* and Lymphoid Enhancer Binding Factor 1 genes [16,17]. Fibroblast growth factor, *Bmp*, sonic hedgehog, tumor necrosis factor and wingless-related integration site are signaling pathways which initiate tooth epithelium during 9th-11th day of embryogenesis [13]. It has also been suggested that failure of normal apoptosis, a key regulating process in tooth morphogenesis, could lead to macrodontia [18,19,20].

Case report

KBG syndrome (OMIM 148050) was initially delineated in 1975 in three families as a “malformation and/or retardation syndrome” [21]. The condition was named after the initials of the last names of these three original families. The common findings among these families were developmental delays, short stature, dysmorphic features, and macrodontia [22]. Reports have shown that males were much more severely affected than females; hence, the condition was considered as X-linked inheritance for several years. Subsequently, an autosomal dominant inheritance pattern was suggested which was confirmed by demonstration of causative *ANKRD11* variants in affected individual. *ANKRD11* gene on chromosome 16q24.3 encodes for a protein inhibitor of ligand-dependent transcriptional activation. Mutations of *ANKRD11* triggers nonsense-mediated decay, resulting in haploinsufficiency and disease phenotype [23].

Oral and craniofacial presentation

A 16-year-old female of mixed ancestry heritage, with a confirmed diagnosis of KBG Syndrome, was referred to the Faculty of Dentistry for an evaluation. She was diagnosed with intellectual and developmental delays. She was also diagnosed with hypertension at 16 years associated with renal disease. Her parents main complaint was “bleeding gums and crooked teeth”.

Table 1 – Genetic conditions associated with macrodontia.

Syndrome	Gene	Clinical features
Otodental syndrome (OMIM* 166750)	FGF3 [†]	Globodontia of primary and secondary dentitions, sparing incisors. Abnormal crown morphology and missing teeth. Bilateral sensorineural hearing loss.
Hemifacial hyperplasia (OMIM* 133900)	Unknown	Enlargement of all tissues- teeth, bone and soft tissues in the area.
KBG syndrome (OMIM* 148050)	ANKRD11 [‡]	Hypertelorism, macrodontia, short stature delayed bone maturation, skeletal anomalies, and developmental delay (IQ less than 80).
Ekman-Westborg-Julin syndrome	Unknown	Multiple macrodontic teeth. Teeth with multituberculism and the presence of central cusps, evaginations and invaginations.
Rabson-Mendenhall syndrome (OMIM* 262190)	INSR [§]	Hyperglycaemia, short stature, prematurely aged facial expression, hyperpigmentation and hyperkeratosis of skin, hirsutism, thick nails, lean appearance, macrodontia, early eruption, crowding and protrusive tongue.
Klinefelter (XXY) syndrome	47, XXY	Macrodontia, dental agenesis, bimaxillary protrusion, larger stature, large head circumference, neurodevelopmental delays, hypertension, genitourinary abnormalities.
Aarskog syndrome (OMIM* 10050)	FGD1	Males have rounded face with a broad forehead, hypertelorism, ptosis, downward slanted palpebral fissures, small nose with anteverted nares, maxillary hypoplasia, long philtrum and typically a normal IQ.
Simpson-Golabi-Behmel syndrome (OMIM* 312870)	GPC3 [¶]	Facial asymmetry, hypertelorism, upward slanting palpebral fissures, broad nose, thin lips, and a prominent mandible. High arched palate, grooved tongue, macrodontia.

* Online mendelian inheritance in man.

[†] Fibroblast growth factor 3.

[‡] Ankyrin repeat domain 11.

[§] Insulin receptor.

^{||} Faciogenital dysplasia 1.

[¶] Glypican 3.

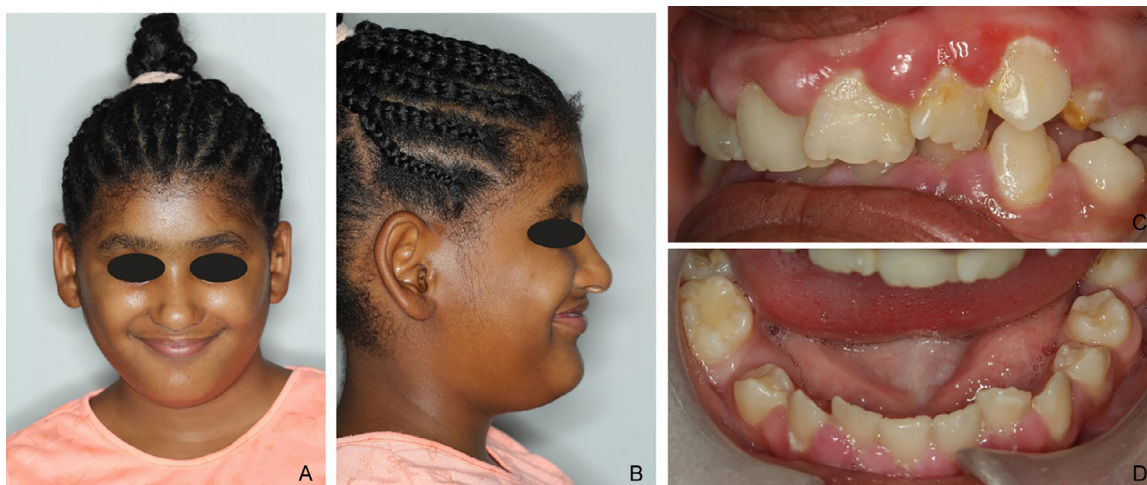

Fig. 1 – (A) Frontal view. (B) Lateral profile. (C) Lateral clinical views of the patient at initial examination showing shovel shaped teeth with enamel hypoplasia and inflammatory gingival hyperplasia. (D) Lower occlusal view.

The extra-oral examination revealed her face to be triangular in shape, although not so apparent, and full, bushy eyebrows. She had a prominent nasal bridge, a bulbous nose and a thin vermilion border of the upper lip. Lip tension is present. Her hair was coarse, and she presented with a low hairline (Fig. 1A and B).

An intraoral examination revealed macrodontia of the upper and lower incisors as well as prominent mamelons on these teeth. The upper incisors were shovel shaped and enamel hypoplasia was evident on the premolars. The patient also presented with marked gingival hyperplasia and in-

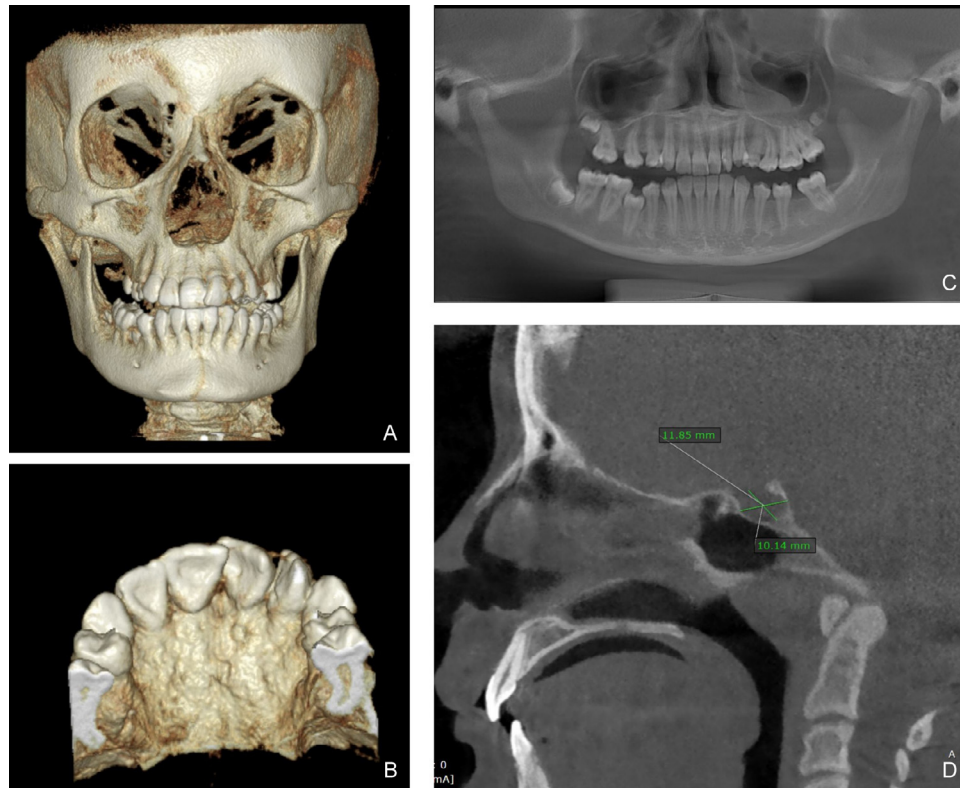


Fig. 2 – (A) 3D reconstruction view (Front) showing flattening of the supraorbital ridges. (B) 3D reconstruction view showing the upper jaw. (C) CBCT-reformatted panorama (at 22 mm thickness). (D) Sagittal slice (selected at the center of the patient) showing an obtuse basal angle (Welcher-basal angle).

flammation, most likely due to substantial plaque aggregates (Fig. 1C and D).

CBCT radiological observations

The CBCT scan revealed a missing maxillary right permanent first molar and mandibular left permanent first molar; although this is better assessed on bitewing radiographs multiple carious lesions of the maxillary and mandibular molars can be noted. The crypts of the maxillary right permanent third molar, maxillary left permanent third molar, and mandibular right permanent third molar were evident, however, the crypt of the mandibular left permanent third molar was absent. Dilaceration of the roots of the maxillary right permanent second premolar and the maxillary left permanent second premolar was noted. The mandibular right permanent second premolar is vertically impacted with incomplete root apex closure (Fig. 2C).

Flattening of the supraorbital ridge noted (Fig. 2A). A Welcher-basal angle of 158.5° was noted, indicating platybasia (Fig. 2D). Platybasia is the flattening of the skull base and a Welcher-Basal angle exceeding 140° is considered diagnostic [24]. The paranasal sinuses also showed abnormalities; aplasia of the frontal sinus and intermediate densities in the left maxillary sinus and ethmoid sinuses were present.

Diagnosis of macrodontia

Larger than normal upper and lower incisor tooth dimensions was noted on clinical exam. Alginate impressions were taken of the maxillary and mandibular arch to create study models. Measurements were taken directly from the casts by two, independent clinicians using callipers. The mean of the measurements from the two examiners were compared to measurements taken from the CBCT (Fig. 2B) and intra-oral dental scans. Our results (Table 2) are compared to that of an unpublished study by di Plaque on tooth dimensions in a South African population [25]. The patient measurements in bold are greater than two standard deviations compared to black and white female South Africans. Posterior teeth were unremarkable in size.

Dental management

The carious lesions and poor oral hygiene were treated conservatively under local anaesthetic. Regular follow-ups were scheduled at six monthly intervals. During this period, her overall oral health status had improved markedly. The patient is scheduled to commence orthodontic treatment.

Table 2 – Mesio-distal tooth dimension comparison.

Tooth number	Black Female (mm*) (SD standard deviation)	Patient (mm*)	White female (mm*) (SD standard deviation)
6	7.88 (SD 0.41)	7.9	7.75 (SD 0.35)
7	7.28 (SD 0.53)	8.45	6.65 (SD 0.57)
8	9.04 (SD 0.49)	10.02	8.62 (SD 0.53)
9	9.04 (SD 0.49)	10.32	8.62 (SD 0.53)
10	5.28 (SD 0.53)	8.37	6.65 (SD 0.57)
11	7.88 (SD 0.41)	8.0	7.75 (SD 0.35)
22	7.10 (SD 0.31)	7.00	6.71 (SD 0.33)
23	6.13 (SD 0.33)	7.05	5.89 (SD 0.37)
24	5.47 (SD 0.31)	6.07	5.35 (SD 0.35)
25	5.47 (SD 0.31)	6.29	5.35 (SD 0.35)
26	6.13 (SD 0.33)	6.92	5.89 (SD 0.37)
27	7.10 (SD 0.31)	7.10	6.71 (SD 0.33)

6, maxillary right permanent canine; 7, maxillary right permanent lateral incisor; 8, maxillary right permanent central incisor; 9, maxillary left permanent central incisor; 10, maxillary left permanent lateral incisor; 11, maxillary right permanent canine; 22, mandibular left permanent canine; 23, mandibular left permanent lateral incisor; 24, mandibular left permanent central incisor; 25, mandibular right permanent central incisor; 26, mandibular right permanent lateral incisor; 27, mandibular left permanent canine; *, millimetre.

Discussion

This report aimed to give a brief overview of macrodontia and presented a case of the rare, KBG syndrome in South Africa. This case illustrates the importance of considering syndromic associations when macrodontia is observed. Members of the dental fraternity may be the first recognize macrodontia which is associated with genetic disorders and can provide a valuable service to their patients by proper referral to a medical geneticist and/or genetic counsellor.

Dental tooth dimensions are known to differ between different populations [26]. It should be noted that several of the patient's anterior teeth fell within normal range of Black South African females [25], even though they appeared to be visibly macrodontic. Conversely, all incisors were macrodontic compared to Caucasian South African females. Because no normative tooth measurements exist to describe South Africans of mixed ancestry, we are reliant on using measurements on other population groups which may not adequately identify tooth size aberrations in all populations. Therefore, although normative values are required, some flexibility is required when attending to individuals of different ethnicities and a clinician should anticipate these differences and use a personalized approach in the diagnosis of all patients [26]. It was also noted that our patient has platybasia. Cranial base anomalies impact on dental therapy in that caution is warranted when a patient's head is manipulated in order to avoid atlanto-axial subluxation and spinal cord compression.

Conclusion

As with many genetic disorders, the dental manifestations are often overshadowed by other more conspicuous and complex syndromic features. Recognition of both the clinical and oral changes that occur in KBG syndrome facilitates accurate diagnosis and appropriate management of this condition.

Ethical considerations

All investigations were undertaken in accordance with ethical standards of the responsible committee on human experimentation (institutional and national), the Declaration of Helsinki as updated in the version promulgated in June 2013 [27], and the Singapore Statement on Research Integrity [28]. Written informed consent for the study and publication of photographs was obtained from the patient's mother. The patient provided ascent.

REFERENCES

- [1] Mrinalini M, Chetan C. True generalized macrodontia in a case of rabson-mendenhall syndrome. *J Oral Maxillofac Surg Med Pathol* 2015;27(3):357–60. doi:10.1016/j.ajoms.2014.04.006.
- [2] King NM, Tsai JS, Wong HM. Morphological and numerical characteristics of the southern Chinese dentitions. Part I: anomalies in the permanent dentition. *Open Anthropol J* 2010;3(2):54–64. doi:10.2174/1874912701003020054.
- [3] Koch G, Poulsen S. *Pediatric dentistry: a clinical approach*. 2nd ed. Chichester: John Wiley & Sons; 2013.
- [4] Canoglu E, Canoglu H, Aktas A, Cehreli ZC. Isolated bilateral macrodontia of mandibular second premolars: a case report. *Eur J Dent* 2012;6(03):330–4. doi:10.1055/s-0039-1698969.
- [5] Patil S, Doni B, Kaswan S, Rahman F. Prevalence of dental anomalies in Indian population. *Clin Exp Dent Res* 2013;5(4):e183–6. doi:10.4317/jced.51119.
- [6] Mainali A, Sumanth K, Denny C, Ongole R. Non syndromic generalised macrodontia. *J Nepal Dent Assoc* 2010;11(2):150–3.
- [7] Turner CG. Advances in the dental search for native American origins. *Acta Anthropogenet* 1984;8(1–2):23–78.
- [8] Rostomyan L, Daly AF, Beckers A. Pituitary gigantism: causes and clinical characteristics. *Ann Endocrinol* 2015;76(6):643–9. doi:10.1016/j.ando.2015.10.002.

- [9] Hannah-Shmouni F, Trivellin G, Stratakis CA. Genetics of gigantism and acromegaly. *Growth Horm IGF Res* 2016;30-31:37–41. doi:10.1016/j.ghir.2016.08.002.
- [10] Eugster EA, Pescovitz OH. Gigantism. *J Clin Endocrinol Metab* 1999;84(12):4379–84. doi:10.1210/jcem.84.12.6222.
- [11] Cirino E. Big teeth: causes and treatment [Internet]. Healthline; 2020. (accessed 2020 Jul 21) <https://www.healthline.com/health/big-teeth#causes>.
- [12] Gulabivala K, Ng Y-L. *Endodontics*. Edinburgh: Elsevier Ltd; 2014. doi:10.1013/1305-7456119092.
- [13] Cakan DG, Ulkur F, Taner T. The genetic basis of dental anomalies and its relation to orthodontics. *Eur J Dent* 2013;7(S 01):S143–7. doi:10.4103/1305-7456.119092.
- [14] Jowett AK, Vainio S, Ferguson MW, Sharpe PT, Thesleff I. Epithelial-mesenchymal interactions are required for *Msx 1* and *Msx 2* gene expression in the developing murine molar tooth. *Development* 1993;117(2):461–70.
- [15] MacKenzie A, Ferguson MW, Sharpe PT. Expression patterns of the homeobox gene, *Hox-8*, in the mouse embryo suggest a role in specifying tooth initiation and shape. *Development* 1992;115(2):403–20.
- [16] Neubüser A, Peters H, Balling R, Martin GR. Antagonistic interactions between FGF and BMP signaling pathways: a mechanism for positioning the sites of tooth formation. *Cell* 1997;90(2):247–255. doi:10.1016/s0092-8674(00)80333-5.
- [17] Peters H, Neubuser A, Kratochwil K, Balling R. Pax9-deficient mice lack pharyngeal pouch derivatives and teeth and exhibit craniofacial and limb abnormalities. *Genes Dev* 1998;12(17):2735–47. doi:10.1101/gad.12.17.2735.
- [18] Kassai Y. Regulation of mammalian tooth cusp patterning by ectodin. *Science* 2005;309(5743):2067–70. doi:10.1126/science.1116848.
- [19] Kim J-Y, Cha Y-G, Cho S-W, Kim E-J, Lee M-J, Lee J-M, et al. Inhibition of apoptosis in early tooth development alters tooth shape and size. *J Dent Res* 2006;85(6):530–5. doi:10.1177/154405910608500610.
- [20] López-Onaindia D, de Amezaga AO, Subirà ME. A case of bilateral macrodontia of mandibular second premolars from a chalcolithic context in the iberian peninsula. *Anthropol Anz* 2015;72(3):359–68. doi:10.1127/anthranz/2015/0462.
- [21] Herrmann J, Pallister PD, Tiddy W, Opitz JM. The KBG syndrome—a syndrome of short stature, characteristic facies, mental retardation, macrodontia and skeletal anomalies. *Birth Defects Orig Artic Ser* 1975;11(5):7–18.
- [22] Morel Swols D, Foster J, syndrome Tekin MKBG. *Orphanet J Rare Dis* 2017;12(1). doi:10.1186/s13023-017-0736-8.
- [23] Gnazzo M, Lepri FR, Dentici ML, Capolino R, Pisaneschi E, Agolini E, et al. KBG syndrome: common and uncommon clinical features based on 31 new patients. *Am J Med Genet A* 2020;182(5):1073–83. doi:10.1002/ajmg.a.61524.
- [24] Pinter NK, McVige J, Mechtler L. Basilar invagination, basilar impression, and platybasia: clinical and imaging aspects, 20; 2016. *Curr Pain Headache Rep*. doi:10.1007/s11916-016-0580-x.
- [25] Pasquale T di. Tooth size prediction formulae: a preliminary study on data derived from a sample of south african white and black patients [Internet]. Semantic Scholar; 2020. <https://www.semanticscholar.org/paper/Tooth-size-prediction-formulae%3A-a-preliminary-study-Pasquale/11bb2d34c7866b0ad446b9f4b73edc7c5d8a612a>. (accessed 2020 oct 21).
- [26] Fernandes TME, Sathler R, Natalício GL, Henriques JFC, Pinzan A. Comparison of mesiodistal tooth widths in caucasian, african and japanese individuals with brazilian ancestry and normal occlusion. *Dental Press J Orthod* 2013;18(3):130–5. doi:10.1590/s2176-94512013000300021.
- [27] General Assembly of the World Medical Association World medical association declaration of helsinki: ethical principles for medical research involving human subjects. *J Korean Am Med Assoc* 2014;57(11):899. doi:10.5124/jkma.2014.57.11.899.
- [28] Resnik DB, Shamoo AE. The singapore statement on research integrity. *Account Res* 2011;18(2):71–5. doi:10.1080/08989621.2011.557296.