

# An implant-supported auricular prosthesis: a team effort between two South African tertiary institutions

GAVM Geerts, G Lombaard

## Introduction

Primary osseo-integration with cranio-facial implants is so reliable that it may be considered routine. Arcuri *et al.*<sup>1</sup> reported that the use of titanium endosseous screw implants proved to be a successful, predictable, and quality-of-life-enhancing technique for prosthetic anchorage in the midface region. Nishimura *et al.*<sup>2</sup> reported a 100% success rate for implants used for auricular prostheses. This may be partly the result of a generous thickness of compact bone in the cranium. The Division of Prosthodontics, School for Oral Health Sciences, University of Stellenbosch and the Department of Dental Services, Faculty of Science, Peninsula Technicon collaborated to provide a maxillofacial service and to create a training opportunity for senior undergraduates at the two tertiary institutions. This article describes the prosthodontic management of an implant-supported auricular prosthesis.

## History

Seven years previously the patient had received extensive burns over large areas of the body, including the skull and face. He received multiple skin grafts to cover the burnt areas on the face and scalp. Any further plastic sur-

**GAVM Geerts**, BChD, MChD

Chairperson, Division of Prosthodontics, Department of Applied Oral Health Sciences, Faculty of Health Sciences, University of Stellenbosch

**G Lombaard**, ND Dentech, Student, Department of Dental Services, Peninsula Technicon, Cape Town

Address for correspondence: GAVM Geerts, Division of Prosthodontics, Department of Applied Oral Health Sciences, Faculty of Health Sciences, University of Stellenbosch, Private Bag XI, Tygerberg 7505. Tel (021) 937-3132, fax (021) 931-2287, e-mail gavmg@maties.sun.ac.za

gery, including reconstruction of the missing right ear with autogenous tissue, was contraindicated because of excessive scar-tissue formation. The plastic surgery department of the Tygerberg Hospital referred the 16-year-old patient to the prosthodontic clinic for the fabrication of an auricular prosthesis.

## Clinical examination of the peri-auricular areas

The right ear was missing (Fig. 1). The right external meatus was located at a lower level than the left external meatus, probably as a result of tissue contraction. Part of the left ear lobe was deformed as a result of scarring. Contraction of the skin and underlying tissue created thick hard-tissue bands that covered the auricular areas and the neck, and deformed the facial features on the right side. The colour of the original skin on the left side differed from the colour of the skin grafts covering the scalp and right auricular area. The patient had lost almost all his hair. He was able to hear on both sides.

## Retention

There were no tissue undercuts for engagement by a prosthesis. The use of adhesives or adhesive tape in this case was unlikely to provide enough retention to keep the prosthesis in place.

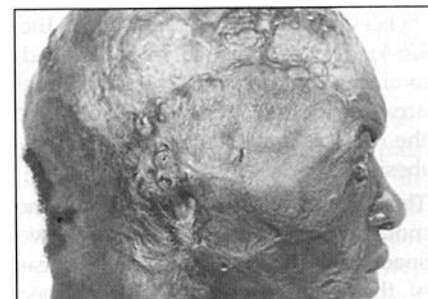


Fig. 1. View of the right side of the skull.

Osseo-integrating implants are the only reliable means of securing the auricular prosthesis. Rubenstein<sup>3</sup> found that bar and clips were the preferred type of attachment used for auricular prostheses manufactured in maxillo-facial prosthetic centres in the USA, Canada and Sweden.

## Implant placement

A preliminary impression of the right side of the head was taken in order to sculpt a wax pattern for the ear. An impression and cast of the left ear was made to help sculpting of the prosthetic ear. The diagnostic wax pattern was utilised for the fabrication of a radiographic/surgical guide for determination of the length and positioning of the implants. Accurate positioning of the implants is critical for the aesthetic result of the prosthesis.

Because of the high success rate of auricular implants, two implants are considered adequate for the retention of an auricular prosthesis.<sup>4</sup> Because of financial constraints the clinical team had to rely on the donation of two implants by the implant manufacturer. Computed tomographic examination revealed that enough bone was available for the placement of two 8.5 mm titanium screw dental implants with a diameter of 3.5 mm close to the designated positions. Four and a half months later the two implants were exposed and healing caps were placed on the two implants. Preparation of the peri-implant skin at the time of exposure was performed. Ideal peri-implant soft tissue could not be achieved despite several attempts, because of overgrowth of tissue. Chloramphenicol ointment (Chloromycetin Applicaps, Pfizer Laboratories, USA) and Coe-Pak (GC, USA) periodontal dressing covered with Tegaderm dressing (3M, Germany)

were applied with pressure on the peri-implant tissue between visits.

## Impressions

Nine weeks after exposure, the skin cuff was measured and transcutaneous abutments 8 mm long were attached to the implants. Markings with an indelible pencil corresponding to the upper, lower, anterior and posterior borders of the contralateral ear were drawn on the skin. Two part pick up type copings and pins were screwed on the transcutaneous abutments. The copings were connected with autocuring acrylic resin supported by loops of dental floss. Plastic tubing, the length of the screwdriver shaft, was secured around the top of the impression copings. The external ear opening was sealed with petroleum-jelly-impregnated gauze. A silicone impression material registered the position of the impression copings. An impression of the auricular area was taken using the boxing technique for making moulages of facial defects described by Ma *et al.*<sup>5</sup> for minimal displacement of soft tissue. The upper hole of the plastic tubings remained uncovered by impression material. After setting of the impression materials, the screws were loosened through the plastic tubing and the moulage was lifted from the face. Brass laboratory abutment replicas were secured onto the impression copings.

## Wax modelling of the prosthesis

The impression was boxed in and the model was poured in yellow stone. The indelible pencil markings on the skin were transferred via the impression to the working model. A cast of the left ear and the pencil markings guided the technician in sculpting the prosthesis using base plate wax. The model was slightly abraded with sandpaper in the tragus area in order to establish close adaptation between skin and prosthesis. The wax pattern was then tried on the patient. Overall shape, thickness and position of the wax ear were evaluated from all angles. Adaptation to the skin was assessed. The final anterior margin was determined. This was difficult because in this area the skin is flat

without any folds or depressions to hide the margin.

## The bar and clip sub-structure

The final shape of the wax replica determined the position of the retentive bar. The thickest part of the wax pattern must provide enough space to keep the future restorative components within the confines of the prosthesis. The shape of the wax pattern and the position of the implants dictated the fabrication of a V-shaped bar providing two clip attachments (Fig. 2). The connection between bar and sleeve is rigid because no forces on the prosthesis are anticipated. The Preciline Preci-horix attachment system (Alphadent NV Ceka Centre, Belgium) was used. The kit consists of burn-out plastic bar and abutment profiles, replaceable plastic riders with three retention levels, ultra-thin inox housings for the perfect fit of the riders in the prosthesis, space maintainers and an insertion accessory.

The abutment profiles were screwed onto the two laboratory abutment analogues. The bar profile was cut to size and luted to the abutments to form the V-shape design of the bar. Extreme care was taken during this procedure not to introduce stresses to the framework. Geo cervical modelling wax (Renfert GmbH, Germany) for crown and bridgework was used.

The profile was kept 1.5 mm clear of the model to enable the patient to clean underneath the bar. The height of the profile had to be kept to the absolute minimum in order to be successfully masked by the prosthesis.

The completed wax pattern was sprued, again avoiding distortion, removed from the model, invested in High-Temp investment (WhipMix Corporation, USA) and cast in Rex-V nickel-chromium (Jeneric/Pentron Inc, USA). It was finished and polished, avoiding abrasion of the functional areas of the bar, to ensure stability of the runners and thus that of the prosthesis.

The finished bar was screwed onto the model where it fitted passively. Two space maintainers serving as replicas of the retention riders were clipped onto the bar in the functional areas and

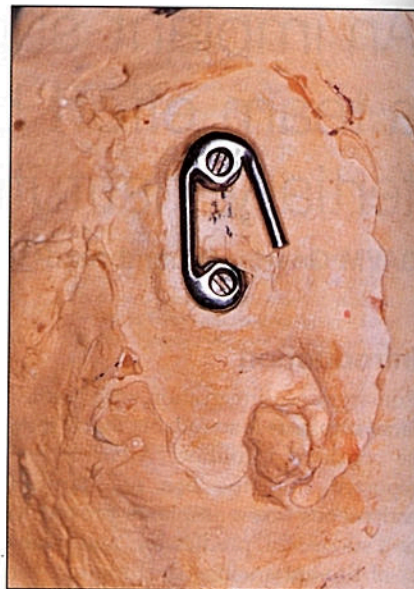

Fig. 2. The V-shaped bar providing two areas for clip attachment.

the rest of the bar was covered in a thin layer of plaster. The metal housings were clipped onto the space maintainers and the structure was covered with a thin layer of Orthocryl auto-polymerising resin (Dentaurum, Germany) to provide strength and rigidity. Petroleum jelly was used to separate resin and stone. The bevelled design of the metal housing mechanically secured it within the resin. The cured acrylic 'cap' with the metal housings seated within it was removed, and the space maintainers replaced with two medium retention riders. The 'cap' was worked off to be as thin as possible. The 'cap' was finished 1.5 mm clear of the model to avoid tissue impingement. It was not polished and undercuts were created for mechanical retention to the silicone rubber prosthesis. After laboratory construction, the metal superstructure was tried onto the transcutaneous abutments to check for passive fit. The wax ear pattern was tried over the superstructure to check the shape and the three-dimensional position again. The patient could clip the cap on and off with ease.

## Corrective wax modelling

The ideal positions for placement of implants for auricular prosthesis, from the technician's point of view, are in the areas of the antihelix and the lower

crus of antihelix. These convex areas of high contour may mask the underlying bar and clip mechanism. However, the abnormal position of the meatus in this case, due to the distortion of the keloid tissue, resulted in a compromised position of the implants. They were located in the regions of the triangular fossa and the chonca. These concave areas of low contour had to be adjusted in order to hide the attachments. The positions of the implants prevented the bar from extending to the lower part of the prosthesis because of a lack of space, hence the V-shaped design. Small vents opening towards the back of the wax prosthesis were provided to assist in the ventilation of the skin covered by the prosthesis.

## Colour matching

It is our experience that the basic skin colours provided by the Cosmesil Elastomer System (Principality Medical Ltd, UK) are not suitable for the dark African skin. The selection of a standard basic skin colour was omitted and colour matching was done by introducing dark master colours and dry pigments directly to the elastomer base. On clear plastic mixing slabs, samples of 10 g of elastomer base without the introduction of catalyst were prepared and mixed with master colours and dry pigment. The clear mixing slab carrying the mixture is held close to the skin for colour matching. When a suitable skin colour was found, flocking was added to further improve colour match. It is standard practice to use the natural ear as a guide to colour when creating a prosthetic replacement. However, there are two exceptions where this principle should not be applied: (i) where the patient has extensive burns affecting the tissues around the margins of the prosthesis, and (ii) where the patient has skin-grafted areas which extend beyond the proposed margins of the prosthesis.<sup>6</sup> The left ear was used to determine the position of three dominant colour areas: a dark, a medium and a light colour area. Three colour samples, one dark, one medium and one light, were prepared to match the colour of the peri-auricular transplanted skin. A hand-drawn picture of the future ear and a digital picture of the

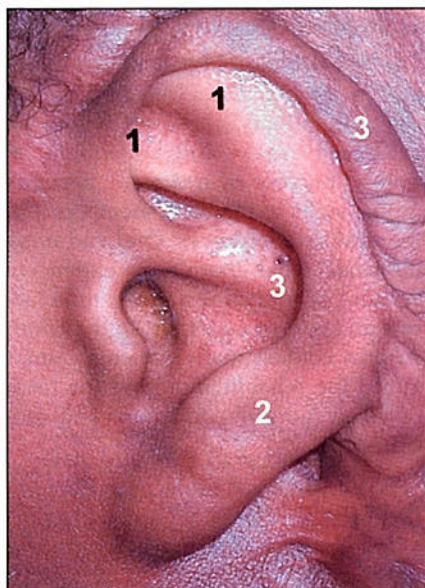


Fig. 3. The three dominant colour areas of the contralateral ear: 1 = light, 2 = medium, 3 = dark.

left ear with the three easily recognisable dominant colour areas (Fig. 3) were provided to help the technician pack the final mixes of silicone base in the correct areas of the mould.

## Investing, curing and finishing

The adjusted wax ear was luted to the working model over the bar and clip ensemble. The edge anterior to the tragus was thinned as much as possible to allow the silicon edge to feather into the natural skin.<sup>6</sup> It was then invested in a mixture of plaster and stone. A three-part mould was made as described by Thomas<sup>7</sup> so that deinvestment of the prosthesis could be achieved without damaging the mould. It also ensured easy placement of the silicone. The wax was boiled out and the mould was separated. Cosmesil has a chemical reaction with cold mould seal, and if used, the curing properties may be affected, resulting in a tacky surface.<sup>7</sup> Therefore the sealant granules supplied with the Cosmesil kit must be mixed with acetone (4 g to 100 ml) to create a suitable separating agent. Three coats of this were applied to all areas of the mould. The recipes recorded by the practitioner for the three shade samples chosen during the colour match were now applied to 30 g of the base material: 15

g of the medium colour were mixed, 10 g of the darker colour and 5 g of the highlight colour. Catalyst and cross-linker were added. The material was packed by spreading the colours in such a way that they ran into one another without creating visible borders. The packed mould was left to cure under a bench press for 24 hours. Curing Cosmesil by exposure to wet heat should not be attempted.<sup>8</sup> After careful deflasking, the flash was removed from the prosthesis with a pair of scissors. Where necessary it was trimmed with a bur similar to the one used for Moloplast-B (DeTax GmbH & Co, Germany). No chemical bond develops between silicon rubber and acrylic resin. It was found that mechanical retention alone between the 'cap' and the prosthetic material was inadequate, as a result of the elasticity of the Cosmesil. It is recommended that both mechanical and chemical retention be used between the acrylic and the silicone material. Dow Corning 1200 OS Primer (Dow Corning Corporation, USA) was used to facilitate chemical retention.

Because the silicon prosthesis has a limited life, the moulds are kept and colour recipes are recorded for future duplication of the prosthesis.

## Final try-on

After curing, the silicone ear was tried on and final extrinsic colouration was necessary. The prosthesis was wiped with acetone. Small quantities of the provided dry pigment in the Cosmesil kit were mixed with one-component silicone prosthesis sealant dissolved in acetone. The colour was applied with a fine paintbrush in areas where slightly darker or lighter colours than the three basic skin colours were required. Superficial texture can also be created at this stage. Fig. 4 shows the final result.

If master colours instead of the basic skin colours are used as a starting point, our experience shows that the available colours in the Cosmesil kit are adequate for producing a prosthesis resembling the dark skin tone of African people. The skills and capability of the practitioner in creating colour greatly influence the success in colour matching.

crus of antihelix. These convex areas of high contour may mask the underlying bar and clip mechanism. However, the abnormal position of the meatus in this case, due to the distortion of the keloid tissue, resulted in a compromised position of the implants. They were located in the regions of the triangular fossa and the chonca. These concave areas of low contour had to be adjusted in order to hide the attachments. The positions of the implants prevented the bar from extending to the lower part of the prosthesis because of a lack of space, hence the V-shaped design. Small vents opening towards the back of the wax prosthesis were provided to assist in the ventilation of the skin covered by the prosthesis.

### Colour matching

It is our experience that the basic skin colours provided by the Cosmesil Elastomer System (Principality Medical Ltd, UK) are not suitable for the dark African skin. The selection of a standard basic skin colour was omitted and colour matching was done by introducing dark master colours and dry pigments directly to the elastomer base. On clear plastic mixing slabs, samples of 10 g of elastomer base without the introduction of catalyst were prepared and mixed with master colours and dry pigment. The clear mixing slab carrying the mixture is held close to the skin for colour matching. When a suitable skin colour was found, flocking was added to further improve colour match. It is standard practice to use the natural ear as a guide to colour when creating a prosthetic replacement. However, there are two exceptions where this principle should not be applied: (i) where the patient has extensive burns affecting the tissues around the margins of the prosthesis, and (ii) where the patient has skin-grafted areas which extend beyond the proposed margins of the prosthesis.<sup>6</sup> The left ear was used to determine the position of three dominant colour areas: a dark, a medium and a light colour area. Three colour samples, one dark, one medium and one light, were prepared to match the colour of the peri-auricular transplanted skin. A hand-drawn picture of the future ear and a digital picture of the

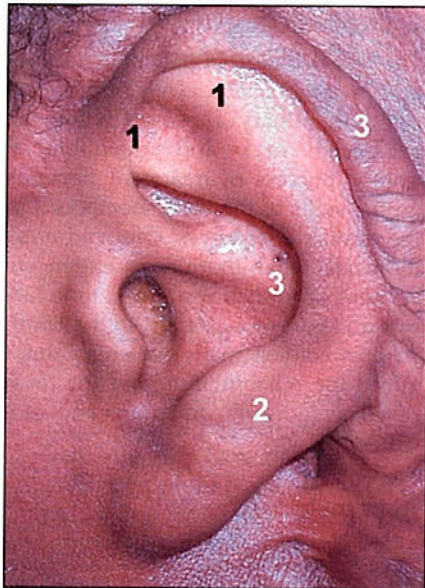


Fig. 3. The three dominant colour areas of the contralateral ear: 1 = light, 2 = medium, 3 = dark.

left ear with the three easily recognisable dominant colour areas (Fig. 3) were provided to help the technician pack the final mixes of silicone base in the correct areas of the mould.

### Investing, curing and finishing

The adjusted wax ear was luted to the working model over the bar and clip ensemble. The edge anterior to the tragus was thinned as much as possible to allow the silicon edge to feather into the natural skin.<sup>6</sup> It was then invested in a mixture of plaster and stone. A three-part mould was made as described by Thomas<sup>7</sup> so that deinvestment of the prosthesis could be achieved without damaging the mould. It also ensured easy placement of the silicone. The wax was boiled out and the mould was separated. Cosmesil has a chemical reaction with cold mould seal, and if used, the curing properties may be affected, resulting in a tacky surface.<sup>7</sup> Therefore the sealant granules supplied with the Cosmesil kit must be mixed with acetone (4 g to 100 ml) to create a suitable separating agent. Three coats of this were applied to all areas of the mould. The recipes recorded by the practitioner for the three shade samples chosen during the colour match were now applied to 30 g of the base material: 15

g of the medium colour were mixed, 10 g of the darker colour and 5 g of the highlight colour. Catalyst and cross-linker were added. The material was packed by spreading the colours in such a way that they ran into one another without creating visible borders. The packed mould was left to cure under a bench press for 24 hours. Curing Cosmesil by exposure to wet heat should not be attempted.<sup>8</sup> After careful deflasking, the flash was removed from the prosthesis with a pair of scissors. Where necessary it was trimmed with a bur similar to the one used for Moloplast-B (DeTax GmbH & Co, Germany). No chemical bond develops between silicon rubber and acrylic resin. It was found that mechanical retention alone between the 'cap' and the prosthetic material was inadequate, as a result of the elasticity of the Cosmesil. It is recommended that both mechanical and chemical retention be used between the acrylic and the silicone material. Dow Corning 1200 OS Primer (Dow Corning Corporation, USA) was used to facilitate chemical retention.

Because the silicon prosthesis has a limited life, the moulds are kept and colour recipes are recorded for future duplication of the prosthesis.

### Final try-on

After curing, the silicone ear was tried on and final extrinsic colouration was necessary. The prosthesis was wiped with acetone. Small quantities of the provided dry pigment in the Cosmesil kit were mixed with one-component silicone prosthesis sealant dissolved in acetone. The colour was applied with a fine paintbrush in areas where slightly darker or lighter colours than the three basic skin colours were required. Superficial texture can also be created at this stage. Fig. 4 shows the final result.

If master colours instead of the basic skin colours are used as a starting point, our experience shows that the available colours in the Cosmesil kit are adequate for producing a prosthesis resembling the dark skin tone of African people. The skills and capability of the practitioner in creating colour greatly influence the success in colour matching.

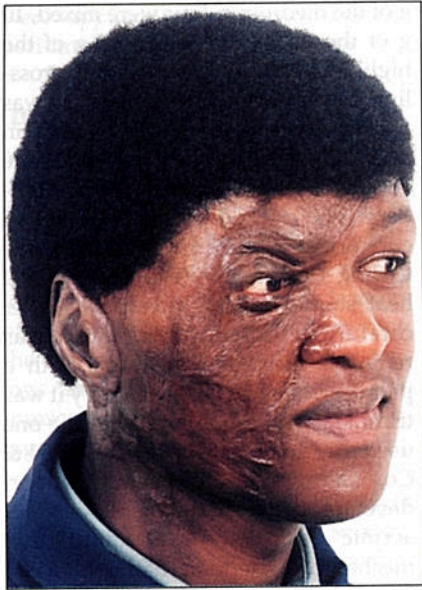

Fig. 4. The auricular prosthesis in position.

### Follow up

Complications after successful integration include peri-abutment skin infections caused by abutment loosening and inadequate soft-tissue preparation.<sup>9</sup> Peri-abutment skin must be thin, non-mobile and non-hairbearing. In this case the formation of excessive scar tissue and keloid after repeated skin preparations prevented the creation of an ideal soft-tissue situation around the transcutaneous abutments. The mobile thick skin cuffs around the 8 mm long abutments made the area susceptible for skin infections. The patient was instructed to clean the area with soap and water twice a day, pat dry and use superfloss or cotton wool to clean underneath the bars and around the abutments. He was instructed to wipe the area with surgical spirits after cleaning and let it dry before replacing the prosthesis. The prosthesis itself is gently wiped with liquid soap and water, rinsed thoroughly and dried daily. He was instructed not to wear the prosthesis overnight. The reaction of the peri-implant tissue will have to be monitored for an indeterminate period.

The enthusiasm of the team involved in the fabrication of the ear and the co-operation of this young patient led to the creation of a hairpiece by a Cape Town based hair-replacing practice, famous for its Afro hairstyles.

### Conclusion

The rehabilitation of patients with oral and maxillofacial defects requires a multidisciplinary approach within an organised oral and maxillofacial unit.<sup>10,11</sup> Success of treatment depends on the skills of the team members and the available resources. Oral and maxillofacial rehabilitation is expensive because of human resources, time factors and cost of materials. In the South African context many patients cannot afford the rehabilitation and the team relies on sponsors, donations and subsidies.

### Acknowledgements

- The School for Oral Health Sciences, the Department of Applied Oral Health Sciences, University of Stellenbosch and PAWC for providing manpower, materials, and prosthetic implant components.
- The Department of Dental Services, Peninsula Technikon, for providing assistance, materials, laboratory implant components and the hair-piece.
- Southern Implants for donating two osseo-integrating fixtures.
- M'Lord and M'Lady of Cape Town for manufacturing the hairpiece at cost price.

### References

1. Arcuri MR, LaVelle WE, Fyler A, Funk G. Effects of implant anchorage on midface prostheses. *J Prosthet Dent* 1997; 78(5): 496-500.
2. Nishimura R, Roumanas E, Sugai T, Lewis S, Montana M. Auricular prostheses and osseointegrated implants: UCLA experience. *J Prosthet Dent* 1995; 73: 553-558.
3. Rubenstein JE. Attachments used for implant-supported facial prostheses: a survey of United States, Canadian, and Swedish centres. *J Prosthet Dent* 1995; 73(3): 262-266.
4. Arcuri MR, Rubenstein JT. Facial implants. *Dent Clin North Am* 1998; 42(1): 161-175.
5. Ma T, Taylor TD, Johnson MA. A boxing technique for making moulages of facial defects. *J Prosthet Dent* 1990; 63(5): 564-566.
6. Pratt G. Auricular prosthesis. *Proceedings of the Institute of Maxillofacial Technology*. 1980; 24: 241-251.
7. Thomas KF. *Prosthetic Rehabilitation*. London: Quintessence Publishing, 1994: Ch 6, 55-60.
8. Cosmesil, a new prosthetic system. The University of Wales and the Institute of Maxillofacial Technology in co-operation with Principality Medical Ltd. No date: 1-20.
9. Brown AMS, Proops DW, Wake MJC. Avoiding complications with craniofacial implants. Tissue integration. In: Laney WR, Tolman DE, eds. *Oral, Orthopaedic & Maxillofacial Reconstruction*. London: Quintessence Books, 1990; 294-302.
10. Wilfaardt JF, Wilkes GH. Craniofacial osseointegration. *J Can Dent Assoc* 1994; 60(9): 805-809.
11. Bishop K. Maxillofacial prosthodontics and reconstruction: a Canadian view. *Br Dent J* 1998; 184(7): 316-320.



SOUTHERN IMPLANTS

012 - 67 1046



■ PROUDLY SOUTH AFRICAN AND BECOMING A MAJOR FORCE IN EUROPE AND THE USA.

■ COMPATIBLE WITH OTHER MAJOR SYSTEMS

■ SURFACE ENHANCED EXTRA-ORAL IMPLANTS

■ SPECIAL PROSTHETICS FOR IMMEDIATE LOADING

■ EXPANDED RANGE OF CERAMIC ABUTMENTS

■ SECOND GENERATION ZYGOMATIC IMPLANT