



Radiological spectrum of metastasis to the oral and maxillofacial region

Chané Nel¹ · André Uys¹ · Liam Robinson¹ · Christoffel J. Nortjé²

Received: 5 September 2020 / Accepted: 27 February 2021 / Published online: 20 March 2021

© The Author(s), under exclusive licence to Japanese Society for Oral and Maxillofacial Radiology and Springer Nature Singapore Pte Ltd. 2021

Abstract

Objective Oral and maxillofacial metastasis may be the first indication of an undiscovered malignancy in a significant number of cases. Therefore, the rationale of this article is to highlight the clinical and radiological presentation of metastatic lesions involving the oral and maxillofacial region. This will serve as a reference for clinicians, who may first encounter patients with possible metastatic lesions in this region.

Methods Histologically confirmed cases of oral and maxillofacial metastasis were retrospectively reviewed over a 30-year period. Twenty-three patients were included in the study. The following clinical information was reviewed: age at diagnosis, gender, medical history, main complaint, site of metastatic tumour, radiological features, preliminary clinical diagnosis and final histological diagnosis.

Results Females were twice as commonly affected, with metastatic lesions three times more likely to occur in the mandible. Common clinical presentations included swelling, pain and paraesthesia, with non-specific dental-related symptoms occurring in a few cases. Fifteen cases presented radiologically with an osteolytic lesion with poorly demarcated margins. Four cases presented with well demarcated lesions with additional signs of destruction. Additionally, four cases showed an osteogenic radiological appearance. In the current population sample, metastasis to the oral and maxillofacial region most commonly originated from the breast.

Conclusion Lesions with poorly demarcated margins with cortical destruction, accompanied by clinical signs of swelling, pain and paraesthesia in the absence of any inflammatory process, should raise suspicion for metastasis. Considering the poor prognosis of these metastatic lesions, the responsibility lies with the clinician to identify these lesions and make appropriate referrals.

Keywords Malignant neoplasms · Metastasis · Undiscovered malignancy · Oral and maxillofacial region · Radiology · Oral and maxillofacial pathology

Introduction

Metastatic tumours to the oral and maxillofacial region are uncommon, but have been reported in both soft tissues and jawbones [1–3]. They are mostly located in the mandible, where the majority occur in the molar region [1, 4,

5]. Metastatic tumours in the oral and maxillofacial region commonly originate from the breast, lung and prostate, followed by the kidney, colorectal region, thyroid gland, liver, stomach, testes and bladder [1, 3, 4, 6].

Metastasis involves the sequential progression of the primary tumour towards invasion and spreading of cancer cells through lymphatic channels or blood vessels. The circulating cancer cells evade the immune system and eventually settle in the microvasculature of the target organ and extravasate through the vessel wall [1, 5, 7]. This process is appropriately termed the metastatic cascade. Many studies indicate that metastasis is a regulated, site-specific, complex process as described by Paget's 'Seed and Soil' theory [1, 7]. The interaction between specific receptors on the surface of disseminating tumour cells and target organ endothelium has

✉ Chané Nel
chane.nel@up.ac.za

¹ Department of Oral Pathology and Oral Biology, School of Dentistry, Faculty of Health Sciences, University of Pretoria, Pretoria, South Africa

² Department of Diagnostics and Radiology, Faculty of Dentistry, University of the Western Cape, Cape Town, South Africa

been implicated as a contributing factor for organ-specific metastasis [7].

The head and neck region is not a preferred site for metastasis. When present, the deposit is often a result of secondary spread from other metastatic lesions, mainly located in the lungs [1, 7]. Other authors have speculated that the metastatic deposit may also arise directly from the primary organ site, bypassing the lungs, via the valveless vertebral venous plexus [5, 7, 8].

The exact pathogenesis of metastatic tumours occurring in the jawbones is unclear [5]. A number of primary malignancies, particularly cancers of the breast, prostate, lungs and kidneys prefer bone for the metastatic process [1, 4, 5, 9]. Skeletal bones with abundant red marrow are favoured sites for metastatic deposits. In general, the jawbones have little active marrow, particularly in elderly individuals who are more prone to metastasis. However, remnants of active hematopoietic marrow can be found in the posterior mandible that may attract metastatic tumour cells [1, 10]. The mandibular blood supply originates from the inferior alveolar artery, whose pathway through the mandible is lengthy. This anatomical feature may be more suitable for the stagnation and gathering of tumour cells [4]. In addition, the mandible is considered a site of high bone turnover, which may also account for the prevalence of metastatic deposits [10].

Metastatic lesions involving the oral soft tissues may present as a non-suspicious gingival reactive lesion, submucosal mass or an area of ulceration [1, 5, 8]. The anterior gingiva is the most common oral soft tissue site for metastasis [2, 8, 11]. Gingival metastasis are equally distributed between the maxilla and mandible, and clinically resemble hyperplastic reactive conditions [11]. Hirshberg et al. suggested that chronic inflammation plays an important role in attracting metastatic cells to the gingiva [5]. Soluble cytokines present in chronically inflamed gingiva may facilitate metastatic progression by stimulating angiogenesis and accelerating the formation of extracellular matrix necessary for the tumour stroma [7]. However, since chronic inflammatory processes of oral soft tissues are common relative to the low incidence of metastasis, it can be assumed that inflammation requires additional factors for cancer development [7].

Due to the rarity of metastatic tumours to the oral and maxillofacial region, their recognition and diagnosis may be difficult. Additionally, their appearance may represent the first indication of an undiscovered malignancy at a distant site or evidence of dissemination of a known primary tumour [1, 2, 6, 12]. Early detection is crucial due to the reported poor prognosis of patients with metastatic lesions [2, 12].

The rationale of this article is to highlight the radiological presentation of histologically confirmed metastatic lesions involving the oral and maxillofacial region. A vast majority

of these lesions are still identified using conventional radiography. Therefore, this article will serve as a reference for clinicians, who may first encounter patients with possible metastatic lesions in this region.

Materials and methods

Histologically confirmed cases of metastasis to the oral and maxillofacial region were retrospectively reviewed over a 30-year period (1989–2019). The data was collected from the archives of two tertiary institutions. Thirty patients presented with metastatic lesions to the oral and maxillofacial region during this period. Seven cases were excluded due to a lack of adequate clinical information or radiographic imaging. All available imaging was used in the radiological analysis, including conventional images (intraoral, panoramic and skull radiographs) as well as specialised imaging [computerised tomography (CT), cone-beam CT (CBCT) and magnetic resonance imaging (MRI)]. The imaging protocols used in each case were based on the manufacturer's instructions for each of the units. The radiological features were evaluated individually by all four authors who have experience in the field of Maxillofacial Radiology. Disagreements were resolved by consensus. The following clinical information was reviewed: age at diagnosis, gender, medical history, main complaint, site of metastatic tumour, radiological features, preliminary clinical diagnosis and final histological diagnosis.

In this study, a metastasis was defined as a secondary tumour derived from a non-contiguous and/or remote malignant neoplasm. In all cases, the metastatic tumour subtype was the same type of malignancy as the primary tumour. In this way, an additional synchronous or metachronous malignancy was ruled out. Direct extensions from an adjacent neoplasm, regional lymph node metastasis and leukaemias/lymphomas were also excluded. The information was analysed, with emphasis on the radiological spectrum of the different metastatic entities.

Results

Following the inclusion criteria, 23 patients presenting with a metastatic lesion in the oral and maxillofacial region were included in the study. Table 1 summarises the main clinicopathological characteristics of the 23 patients. The sample consisted of 8 males and 15 females (1:1.9 male to female ratio) with a mean age of 54 years (range 1–77 years). Ten patients presented with oral and maxillofacial metastasis as the first indication of an undiscovered malignancy at a distant site. Three additional patients (Cases 7, 10 and 23)

Table 1 Clinicopathological characteristics of patients with metastasis to the oral and maxillofacial region

Case	Age at diagnosis	Gender	Medical History	Main complaint	Site of tumour	Imaging available	Radiological features		Preliminary clinical diagnosis	
							Borders	Density Effect		
Metastatic colorectal adenocarcinoma										
1	73	♂	N-C	Painless ulcer	Mnd corpus	CBCT	WD ^a	OL	CD	Squamous cell carcinoma
2	71	♀	N-C	Pain, paraesthesia and swelling	Mnd corpus	PAN, CBCT	PD	OL	CD	Squamous cell carcinoma
3	68	♂	Colorectal adenocarcinoma	Non-healing extraction socket, pain, swelling and tooth mobility	Mnd corpus	PAN, CBCT	PD	OL	CD	Osteomyelitis
Metastatic prostate adenocarcinoma										
4	63	♂	Prostate adenocarcinoma	Proptosis and swelling	Mx and zygomatic bones	CBCT	PD	OG	BE	Fibro-osseous lesion, metastatic lesion
5	77	♂	N-C	Epiphora and swelling	Mx	PAN	PD	OL	CD	Malignant sinonasal tumour
Metastatic pulmonary adenocarcinoma										
6	63	♀	Pulmonary adenocarcinoma with liver metastasis	Paraesthesia, swelling and tooth mobility	Mnd corpus	PAN	PD	OL	CD	Metastatic lesion
Metastatic follicular thyroid carcinoma										
7	60	♀	History of thyroidectomy (reason unknown)	Blindness, headaches and swelling	Skull base	CT, MRI	PD ^b	OL	CD, SI	Chordoma, chondrosarcoma
8	75	♀	N-C	Swelling	Mnd corpus	PAN	WD	OL	CD, RR, BE, #	Ameloblastoma
9	65	♀	N-C	Painless ulcer and swelling	Mnd corpus and ramus	PAN	PD	OL	CD	Osteosarcoma, intrabony malignancy
Metastatic neuroendocrine carcinoma										
10	27	♂	Abdominal mass (diagnosis unknown)	Painless ulcer and swelling	Mx	CBCT	PD	OL	CD, BE, RR, TD	Malignant sinonasal tumour, lymphoma
11	44	♀	N-C	Swelling	Mnd ramus	PAN	PD	OG	BE	Fibro-osseous lesion
Metastatic breast adenocarcinoma										
12	76	♀	Breast adenocarcinoma	Swelling	Mnd ramus	PAN, CT	PD	OG	CD, BE	Fibro-osseous lesion, metastatic lesion
13	35	♀	Breast adenocarcinoma	Pain and paraesthesia	Mnd corpus	PAN, CT	WD ^c	OL	CD	Metastatic lesion
14	62	♀	Breast adenocarcinoma	Paraesthesia and swelling	Mnd corpus	PAN	PD	OL	CD, PR	Metastatic lesion
15	60	♀	N-C	Non-healing extraction socket, pain, swelling and tooth mobility	Mnd corpus and ramus	PAN, Skull view	PD	OL	CD, RR, #	Osteosarcoma, osteomyelitis

Table 1 (continued)

Case	Age at diagnosis	Gender	Medical History	Main complaint	Site of tumour	Imaging available	Radiological features		Preliminary clinical diagnosis	
							Borders	Density Effect		
16	70	♀	Breast adenocarcinoma	Paraesthesia and swelling	Mnd corpus	PAN	WD	OL	BE	Metastatic lesion
17	65	♀	N-C	Pain and swelling	Mx and zygomatic bones	CT	PD	OG	BE, CD, RR	Osteosarcoma
Metastatic hepatocellular carcinoma										
18	46	♀	N-C	Pain and swelling	Mnd corpus	PAN	PD	OL	CD, RR	Intrabony malignancy
Metastatic cervical adenocarcinoma										
19	34	♀	Squamous cell carcinoma of the cervix and pulmonary adenocarcinoma	Non-healing extraction socket and swelling	Mnd corpus	PAN	PD	OL	CD	Post extraction granulation tissue
Metastatic retinoblastoma										
20	11	♂	Retinoblastoma	Swelling	Mnd corpus	Periapical, PAN	PD	OL	CD, TD	Metastatic lesion
Metastatic melanoma										
21	43	♂	Melanoma	Pain and TMJ dysfunction	Two lesions (Mnd ramus and condyle)	PAN, Skull view, MRI	PD ^d	OL	CD	Metastasis
Metastatic pancreaticobiliary adenocarcinoma										
22	63	♂	N-C	Painless ulcer	Mx	PAN	PD	OL	CD, BE, TD	Lymphoma
Metastatic neuroblastoma										
23	1	♀	Three abdominal masses (diagnosis unknown)	Swelling	Mnd symphysis	Skull view, CT	PD	OL	CD, BE, RR, TD	Burkitt lymphoma

♀: Female, ♂: Male, N-C non-contributory, Mnd mandible, Mx maxilla, TMJ temporomandibular joint, PAN panoramic radiograph, CT computerised tomograph, CBCT cone-beam CT, MRI magnetic resonance imaging, WD well demarcated, PD poorly demarcated, OL osteolytic, OG osteogenic, CD cortical destruction, TD tooth displacement, RR root resorption, PR periosteal reaction, BE bony expansion, # Pathologic fracture, SI soft tissue infiltration

^aWell demarcated with loss of demarcation in the anterior and posterior regions

^bPoorly demarcated on CT and well demarcated on MRI

^cWell demarcated on panoramic radiograph, poorly demarcated on CT

^dPoorly demarcated on panoramic radiograph and well demarcated on MRI

reported a vague medical history, which was later linked to a primary tumour. Therefore, 13 out of the 23 total cases of oral and maxillofacial metastasis prompted additional clinical work-up, resulting in the diagnosis of the primary tumour.

The common clinical presentations included swelling (19/23 cases), pain (7/23 cases) and paraesthesia (5/23 cases). Three cases presented with a non-healing extraction socket as the main clinical finding (Fig. 1). Additionally, two patients presented with non-specific dental-related symptoms, such as tooth mobility and temporomandibular joint dysfunction (Fig. 2). Metastatic lesions were three times more likely to occur in the mandible (17/23 cases) compared to the maxilla (5/23 cases). The posterior regions of the mandible were the most frequently affected sites (16/23 cases). Primary tumour sites

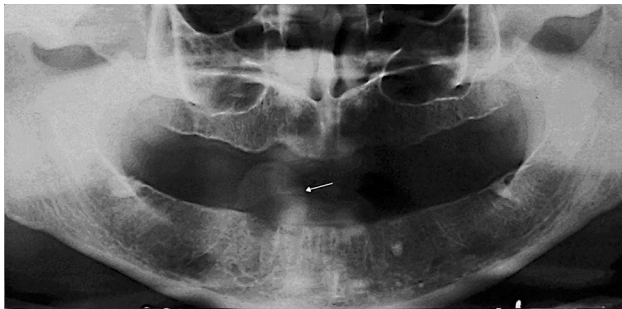


Fig. 1 Case 19: Panoramic radiograph showing a dome-shaped soft tissue lesion (arrow) protruding from a non-healing extraction socket. The lesion was associated with erosion of the underlying alveolar cortex. The lamina dura of the extraction socket was destroyed, appearing osteolytic with poorly demarcated margins

included the breast (6/23 cases), colorectal region (3/23 cases), thyroid gland (3/23 cases), prostate, and neuroendocrine system (2/23 cases each). Carcinomas, in particular adenocarcinoma, made up the majority of metastatic lesions included in this study.

The radiological appearance of an osteolytic lesion with poorly demarcated margins was present in 15 cases (Figs. 3, 4, 5, 6 and 7). Four cases presented with lesions that were well demarcated with additional signs of destruction (Fig. 8). In some instances, the demarcation of the same lesion varied between different imaging modalities (Fig. 9). Four cases showed an increased radiodensity/osteogenic radiological appearance, with metastasis in these cases arising from prostate, neuroendocrine and breast origin (Figs. 10, 11 and 12). Twenty cases showed prominent cortical bone destruction, with pathological fractures reported in two cases, and a periosteal reaction in a single case (Fig. 5). Bone expansion was less prominent, seen in nine cases. In the 12 cases where teeth were involved, six cases showed evidence of root resorption and four cases showed tooth/teeth displacement. Only a single case showed radiological evidence of soft tissue infiltration by the metastatic tumour.

Discussion

Metastatic tumours to the oral and maxillofacial region are rare, comprising 1–3% of all malignant oral neoplasms [1, 13, 14]. This is evidenced by the relatively small sample size generated over a 30-year period in the current study. Metastasis may occur in oral soft tissues, jawbones or both [5].

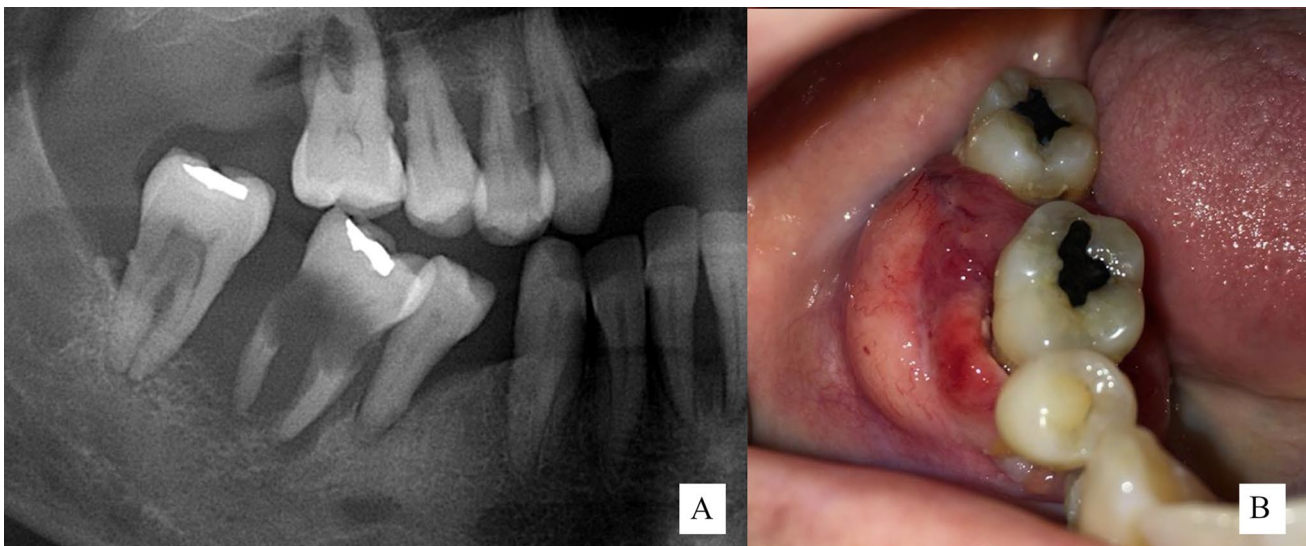


Fig. 2 Case 6: **a** Cropped panoramic radiograph showing a poorly demarcated, erosive lesion of the alveolar bone in the posterior mandibular corpus. **b** Intraoral clinical image showing an ulcerative, fungating soft tissue mass surrounding a mobile first molar

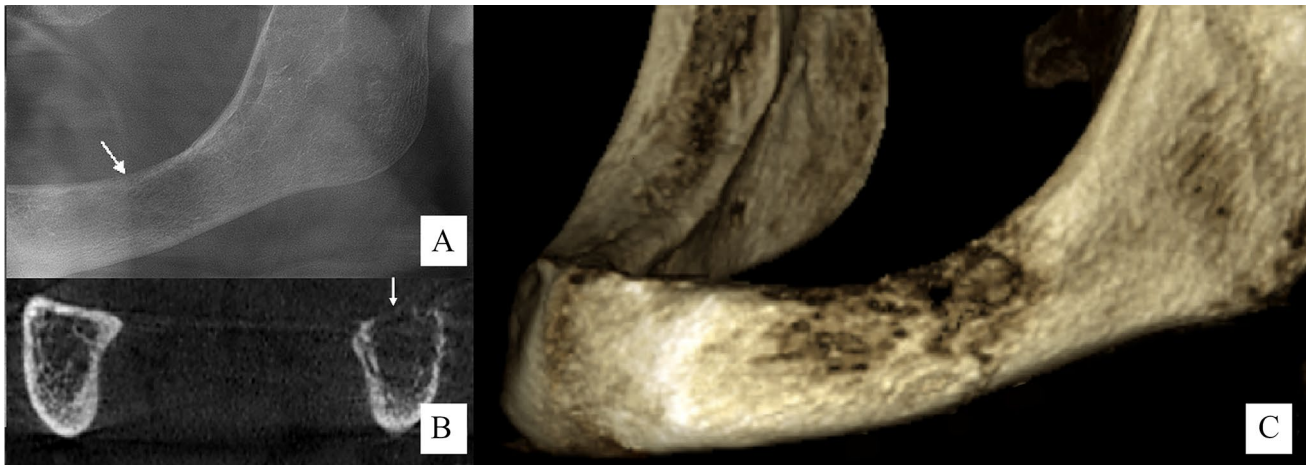


Fig. 3 Case 2: **a** Cropped panoramic radiograph illustrating slight density changes in the superior cortex of the left mandibular corpus (arrow). **b** Coronal (arrow) and **c** three-dimensional (3D) cone-beam

computerised tomography (CBCT) imaging showing superficial erosion of the superior and buccal cortex. Additionally, a loss of trabecular bone architecture was visualised

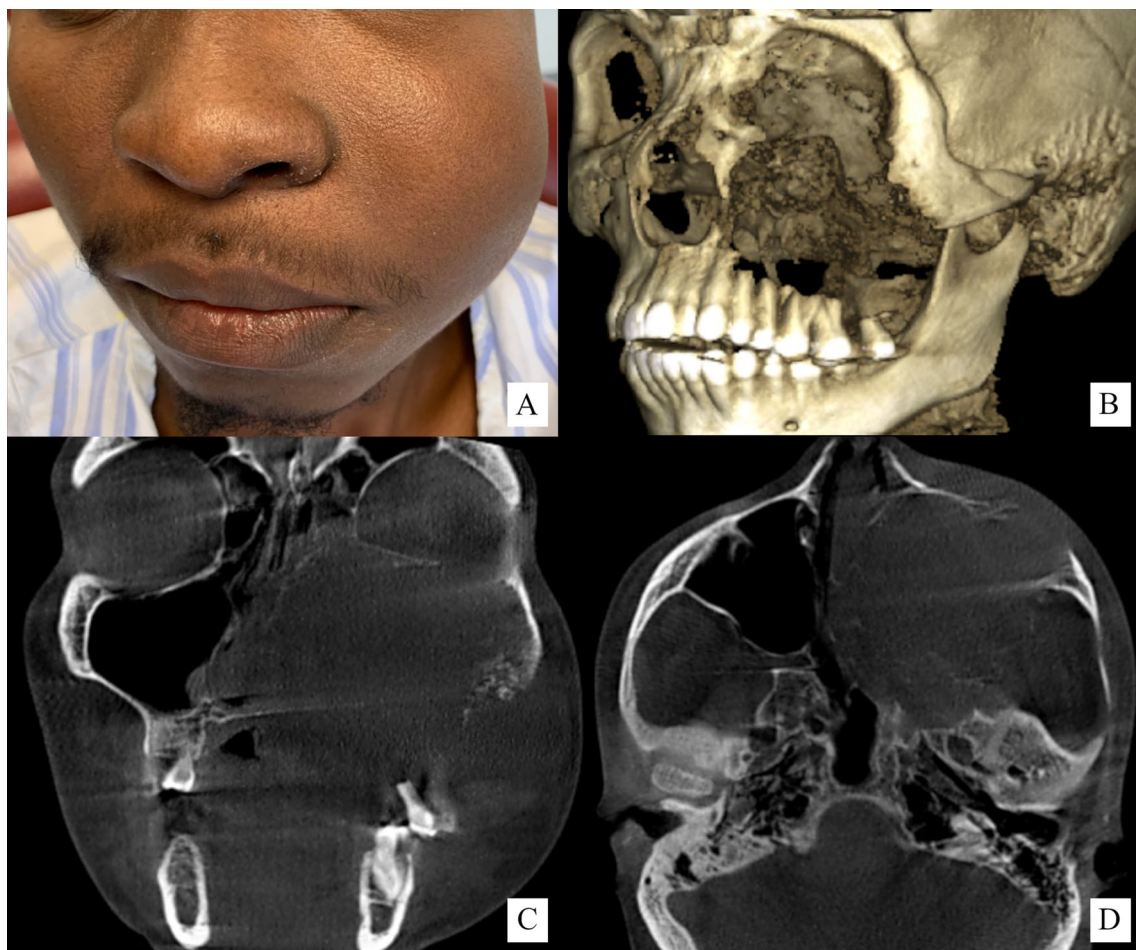


Fig. 4 Case 10: **a** Clinical image showing a large swelling involving the left side of the face. **b** 3D reconstruction **c** coronal and **d** axial CBCT imaging showing a lesion of soft tissue density infiltrating the

left maxillary sinus. The lesion caused significant expansion with destruction of the left lateral nasal wall, inferior orbital border, hard palate, zygoma and maxillary alveolus

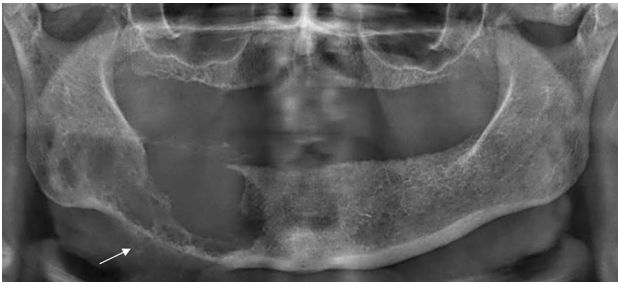


Fig. 5 Case 14: Panoramic radiograph showing a poorly demarcated osteolytic lesion in the right mandible with a spiculated periosteal reaction at the inferior border (arrow)

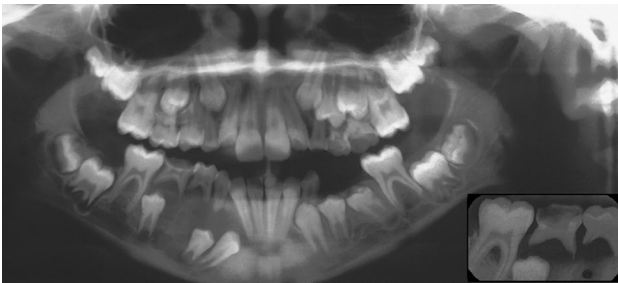

Fig. 6 Case 20: Panoramic and periapical radiograph (insert) showing a poorly demarcated osteolytic lesion extending from the right permanent mandibular lateral incisor to the right permanent first molar. The lesion resulted in displacement of the unerupted right permanent mandibular canine and premolars

Oral and maxillofacial metastasis is a regulated, complex process, with some tumours showing a preference for the jawbones over soft tissue [5, 8, 15, 16]. Soft tissue metastasis may erode the underlying bone, whereas bone metastasis may extend into the overlying soft tissues [8, 17]. Therefore, in many instances, determining the primary site of involvement may prove difficult. In the current sample, the epicentre of the metastatic deposit appeared to be within bone in the majority of cases (19/23 cases).

Most metastases to the oral and maxillofacial region are diagnosed in patients in their fifth to seventh decades [1, 5, 12]. In the current study, the mean age of 54 years and a female predominance is consistent with previous studies [2, 8, 14]. In contrast, other studies revealed an almost equal gender distribution or a male predominance [2, 5, 10].

In the current sample, swelling, pain and paraesthesia were common signs and symptoms associated with metastasis to the oral and maxillofacial region. This finding is consistent with previous reports in the literature [5, 8, 10]. Numb-chin syndrome describes paraesthesia in the region innervated by the inferior alveolar nerve and in most instances points to mandibular ramus metastasis [2]. In the current sample, all patients presenting with

paraesthesia had metastases involving the mandibular corpus. Paraesthesia represents a significant clinical finding that is associated with a poor prognostic outcome [4, 9, 17, 18]. Other non-specific symptoms, such as tooth mobility, odontogenic infection with pain and temporomandibular joint dysfunction, may also be present [1, 2, 8, 16]. Moreover, there are numerous reported cases of exodontia preceding the discovery of a metastatic lesion [9]. Several cases reported a soft tissue mass protruding from a non-healing socket within 29 days [9, 19]. The metastatic lesion may have been present before exodontia, mimicking dental pain or mobility, resulting in extraction of the offending tooth. In other instances, the extraction process and subsequent inflammatory response may have created a favourable, nutrient-rich environment that promoted circulating malignant cells to settle in this region [5, 9]. These non-specific symptoms were seen in the current sample.

Oral and maxillofacial metastases are located in the mandible in 80–90% of cases, with the molar region being the most frequently involved site, as seen in the current sample [1, 5, 8]. Hashimoto et al. postulated that these are favourable sites for early metastasis due to the presence of hematopoietic cells in normal adults [3]. These hematopoietically active sites may serve as a favourable niche attracting metastatic tumour cells [7]. Only in advanced stages of disease did tumour cells appear in the anterior part of the mandibular body [3]. In contrast, the adult maxilla lacks active hemopoiesis, which may result in tumours metastasising to the mandible much more frequently [3].

The identification of oral and maxillofacial metastasis on routine radiographic examination, particularly in the early stages, may be difficult [6, 8]. Notable radiological signs are generally only detectable after a marked change in bone density. It has been reported in the literature that in a significant number of cases, no apparent radiological change could be visualised in histologically confirmed jawbone metastases [3, 5, 20]. In general, radiological signs of well demarcated borders points to benign neoplastic or cystic lesions. In contrast, poorly demarcated lesions generally suggest an infectious or malignant neoplastic process [21]. In the majority of cases, metastatic lesions will follow the status quo and present with poorly demarcated, osteolytic changes and radiological signs of destruction [2, 5, 8, 14]. The latter includes root resorption, cortical destruction and soft tissue infiltration. Radiologically, most cases in the current sample presented as destructive, poorly demarcated osteolytic lesions. Cortical destruction was the most prominent radiological feature, with bone expansion seen in a limited number of cases. Some lesions, on the other hand, can mimic a benign lesion radiologically. In the current study, this finding was seen in one case where the radiological appearance yielded a benign provisional diagnosis.

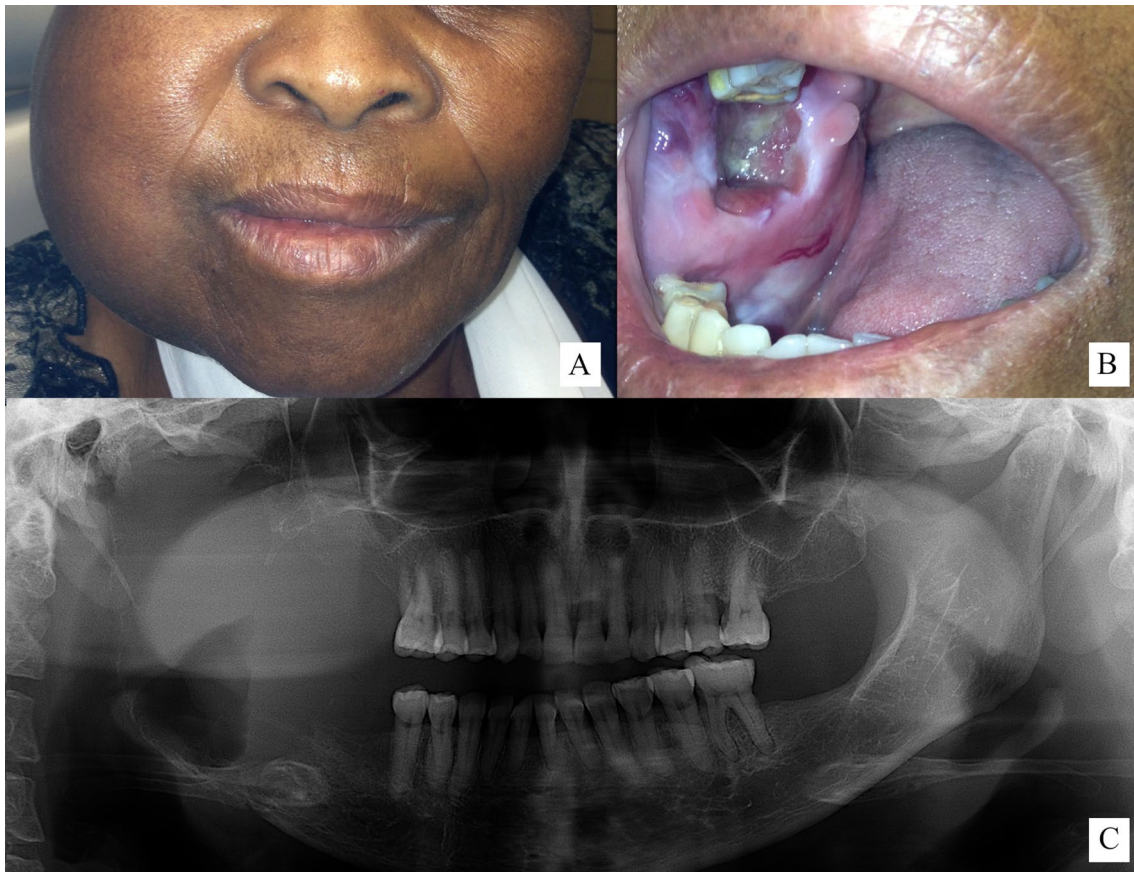


Fig. 7 Case 9: **a** Extraoral clinical image showing a swelling involving the right side of the face. **b** Intraoral clinical image showing an ulcerative lesion with rolled margins involving the right buccal

mucosa. **c** Panoramic radiograph showing a poorly demarcated osteolytic lesion resulting in cortical destruction of the right corpus and ramus

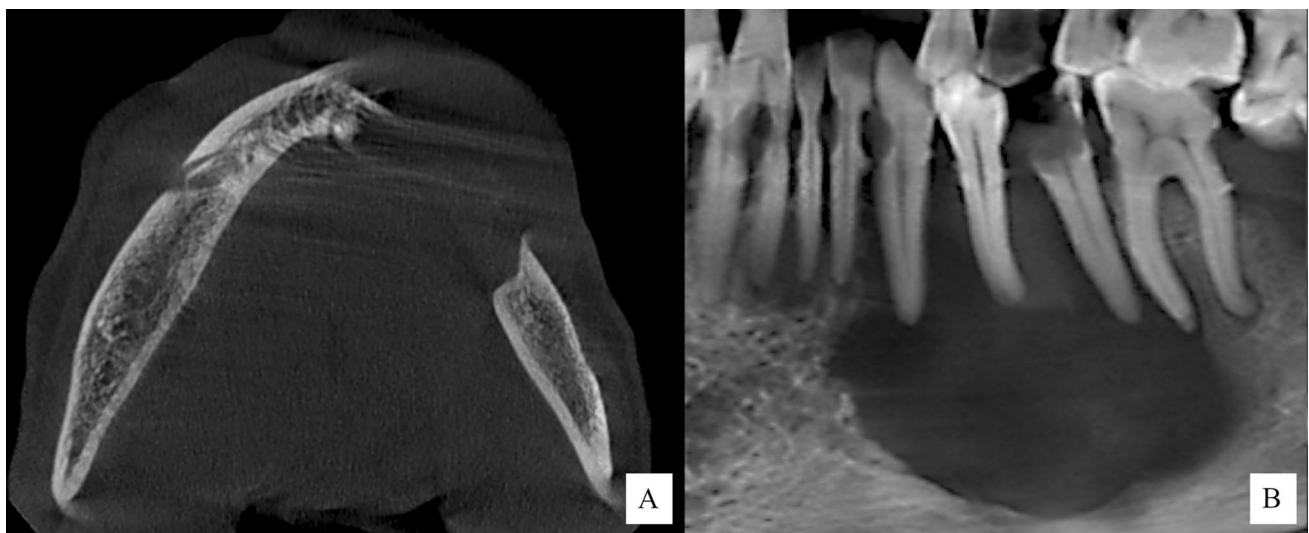


Fig. 8 Case 1: **a** Axial and **b** panoramic reconstruction from the CBCT data set. CBCT imaging showing an osteolytic lesion with well demarcated borders. The lesion showed focal areas of loss of demarcation with associated destruction of buccal and lingual cortices

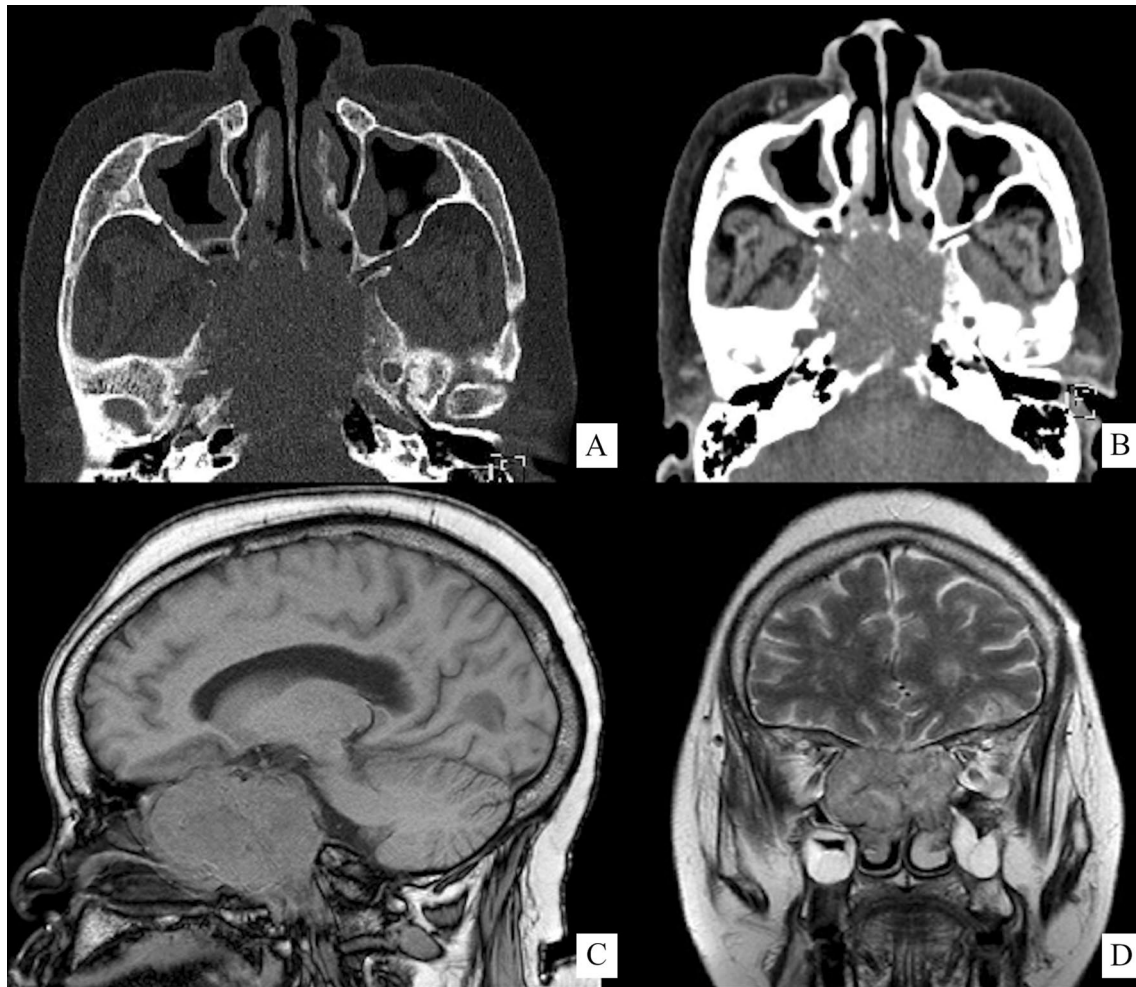


Fig. 9 Case 7: **a** Axial bone and **b** soft tissue levels of CT imaging showing a poorly demarcated osteolytic lesion that resulted in significant bone destruction with intracranial extension at the superior margins. Anteriorly, the mass extended to involve the sphenoid, ethmoid

and maxillary sinuses. **c** Sagittal and **d** coronal MRI showing a well demarcated soft tissue tumour encasing the carotid arteries and optic nerves laterally

The radiographic density of metastatic tumours to bone is dependent on the nature or origin of the primary tumour, and whether the malignant cells secrete osteoblast or osteoclast stimulating factors [5]. In approximately 18% of cases, metastasis can present with increased radiodensity, frequently arising from prostatic or breast origin [4–6, 14]. This corresponds to findings in the current sample, with four cases having an osteogenic appearance. Several studies found that in some instances the same disease process can present with different radiological features [6, 20]. In the current sample, metastases from both prostatic and breast origin presented as either an osteolytic or osteogenic lesion.

Due to the inherent limitations of some radiographic examinations, the full extent of radiological features of each case could not be completely described. For example, two-dimensional radiographs are unable to completely assess the degree of destruction and/or expansion. This implies that

features such as cortical destruction and soft tissue infiltration may be underreported in cases where only conventional imaging was performed. This is evident in the current sample where lesions appeared well demarcated on a panoramic radiograph, yet subsequent advanced imaging revealed additional destructive signs. CBCT imaging was also advantageous in illustrating minor bony changes when compared to panoramic radiography, as was illustrated in case 2. Furthermore, two-dimensional radiographs and CBCT imaging are unable to view soft tissue involvement and extension. Although the majority of these lesions are still identified through the utilisation of conventional imaging methods, this emphasises the need for specialised imaging protocols in the management of patients with metastatic disease.

Adjunct special investigations of suspicious lesions are important, as metastasis to the oral and maxillofacial region may be the first sign of a primary malignant tumour [5, 10,

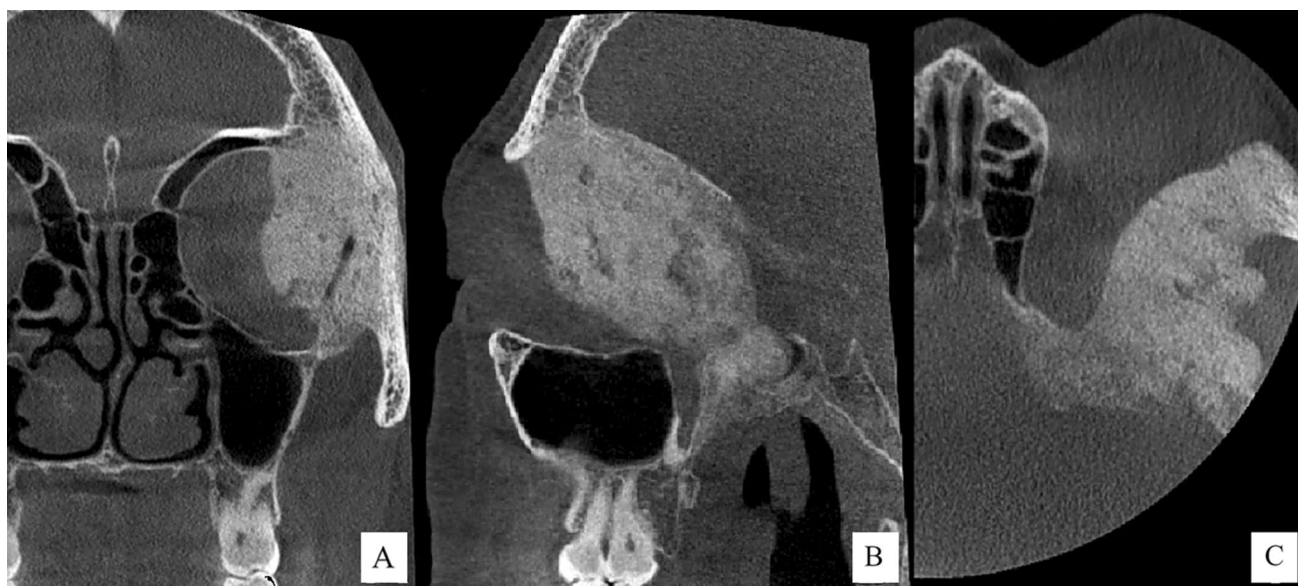


Fig. 10 Case 4: **a** Coronal, **b** sagittal and **c** axial CBCT imaging showing a radiopaque mass with focal osteolytic areas involving the left zygomatic and maxillary bones. Additionally, the left lateral and

posterior orbital walls were also affected. The lesion extended to involve the sphenoidal sinus and base of the left anterior and middle cranial fossae

13]. This number was particularly high in the current sample, with 13 out of 23 metastatic lesions presenting as the first sign of a primary malignant tumour. Once a metastatic tumour is suspected, appropriate referral for an oncologic work-up is required. Advanced imaging, scintigraphy and regional investigations should be performed to confirm the origin and identify other areas of secondary spread [1]. PET/CT imaging has higher sensitivity and specificity to detect bony changes, compared with CT and MRI [2, 20, 22]. Additionally, a PET/CT scan can detect 30% of primary tumours missed by conventional imaging, and is therefore recommended for metastatic lesions of unknown primary site [22].

The most common primary tumours metastasising to the oral and maxillofacial region include the breast, lung and

prostate, followed by the kidney, colorectal region, thyroid gland, liver, stomach, testes and bladder [1, 3, 4, 6]. However, differences in primary site exist between various geographic areas, which may in part reflect differences in the prevalence of primary malignancies in these countries [2, 7, 14]. In the current population sample, metastasis to the oral and maxillofacial region commonly originated from the breast followed by the colorectal region and thyroid gland.

The diagnosis of metastasis to the oral and maxillofacial region is challenging, both for the clinician and the pathologist. In cases with known primary tumours, the histological findings of the metastatic lesion can be compared with that of the primary tumour [4, 7, 8, 12]. However, in cases where the primary origin of the metastasis is unknown, special immunohistochemical stains may be required to determine the lineage of the primary tumour [5, 7, 8].

Jaw metastasis is indicative of advanced disease and is associated with a poor prognosis, where a significant number of patients succumb to disease within a year [8, 12, 15, 23]. Reported survival times range between 7 and 31 months [4, 5, 8]. The prognosis for metastasis to the oral soft tissues is even graver [8]. Surgery with adjunct radiation therapy or chemoradiotherapy provided a significant improvement in survival rates of patients presenting with craniofacial metastases [4, 12, 13].

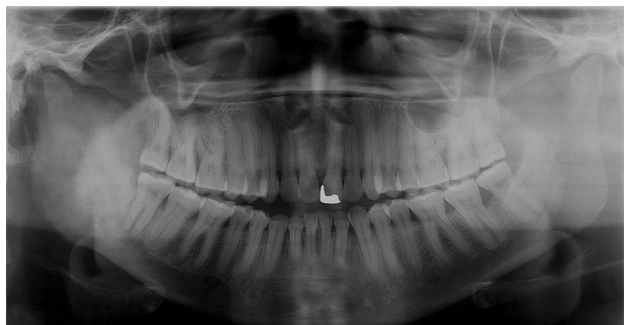


Fig. 11 Case 11: Panoramic radiograph showing a poorly demarcated radiopaque lesion that resulted in significant expansion of the right mandibular ramus, sigmoid notch and coronoid process. The borders of the lesion blended into the surrounding bone

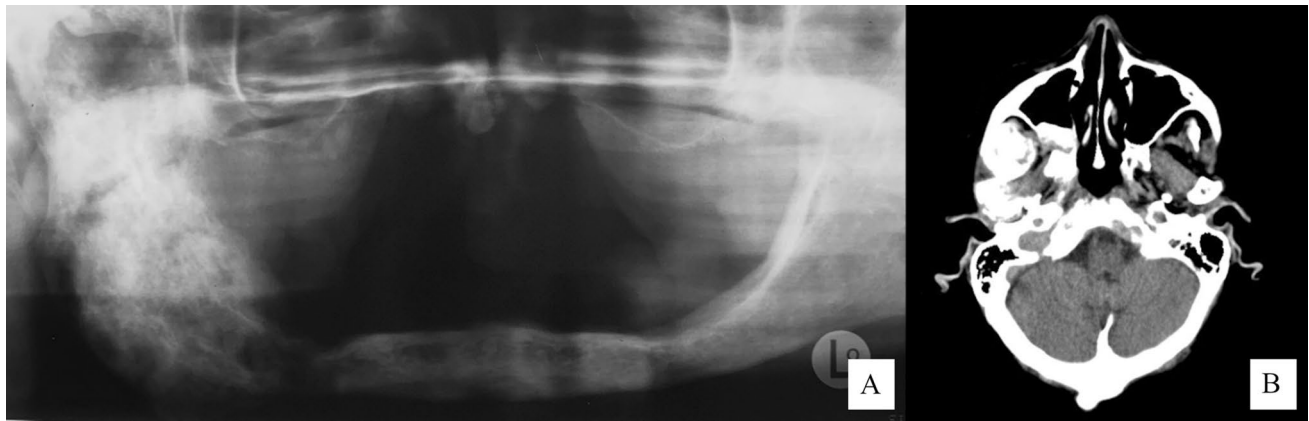


Fig. 12 Case 12: **a** Panoramic radiograph and **b** axial CT imaging showing a poorly demarcated, radiopaque lesion with focal osteolytic areas in the right mandibular ramus. There was associated expansion of the ramus, coronoid and condyle

Conclusion

Metastatic lesions in the oral and maxillofacial region may be the first sign of a distant malignant tumour in a significant number of cases. Lesions with poorly demarcated margins with cortical destruction, accompanied by clinical signs of swelling, pain and paraesthesia in the absence of any inflammatory process, should raise suspicion for metastasis. Taking into account the grave prognosis, the responsibility lies with the clinician to identify these lesions and make appropriate referrals.

Funding This research did not receive any specific grant from funding agencies in the public, commercial, or not-for-profit sectors.

Declarations

Conflict of interest All authors have indicated that they have no potential conflicts of interest and no financial relationships relevant to this article to disclose.

Ethical approval The study was conducted following approval by the Faculty of Health Sciences Research Ethics Committee, University of Pretoria (295/2020). All procedures followed were in accordance with the ethical standards of the responsible committee on human experimentation (institutional and national) and with the Helsinki Declaration of 1975, as revised in 2008. This article does not contain any studies with animal subjects performed by any of the authors.

References

- Kumar GS, Manjunatha BS. Metastatic tumours to the jaws and oral cavity. *J Oral Maxillofac Pathol.* 2013;17:71–5. <https://doi.org/10.4103/0973-029X.110737>.
- Lim SY, Kim SA, Ahn SG, Kim HK, Kim SG, Hwang HK, Kim BO, Lee SH, Kim JD, Yoon JH. Metastatic tumours to the jaws and oral soft tissues: a retrospective analysis of 41 Korean patients. *Int J Oral Maxillofac Surg.* 2006;35:412–5. <https://doi.org/10.1016/j.ijom.2005.12.001>.
- Hashimoto N, Kurihara K, Yamasaki H, Ohba S, Sakai H, Yoshida S. Pathological characteristics of metastatic carcinoma in the human mandible. *Oral Pathol.* 1987;16:362–7. <https://doi.org/10.1111/j.1600-0714.1987.tb00709.x>.
- Cai Z, Zhu C, Wang L, Zhu L, Zhang Z, Zhu H, Wang Y. A retrospective study of six patients with mandibular metastatic carcinoma. *Oncol Lett.* 2016;11:3650–4. <https://doi.org/10.3892/ol.2016.4484>.
- Hirshberg A, Shnaiderman-Shapiro A, Kaplan I, Berger R. Metastatic tumours to the oral cavity—pathogenesis and analysis of 673 cases. *Oral Oncol.* 2008;44:743–52. <https://doi.org/10.1016/j.oraloncology.2007.09.012>.
- Carmichael FA, Mitchell DA, Dyson DP. Case report. Two contrasting radiological presentations of prostatic adenocarcinoma in the jaws. *Dentomaxillofac Radiol.* 1996;25:283–6. <https://doi.org/10.1259/dmfr.25.5.9161183>.
- Hirshberg A, Berger R, Allon I, Kaplan I. metastatic tumors to the jaws and mouth. *Head Neck Pathol.* 2014;8:463–74. <https://doi.org/10.1007/s12105-014-0591-z>.
- Owosho AA, Xu B, Kadempour A, Yom SHK, Randazzo J, Ghossein RA, Huryan JM, Estilo CL. Metastatic solid tumors to the jaw and oral soft tissue: a retrospective clinical analysis of 44 patients from a single institution. *J Cranio-Maxillofacial Surg.* 2016;44:1047–53. <https://doi.org/10.1016/j.jcms.2016.05.013>.
- Hirshberg A, Leibovich P, Horowitz I, Buchner A. Metastatic tumors to postextraction sites. *J Oral Maxillofac Surg.* 1993;51:1334–7. [https://doi.org/10.1016/S0278-2391\(10\)80138-7](https://doi.org/10.1016/S0278-2391(10)80138-7).
- D’Silva NJ, Summerlin DJ, Cordell KG, Abdelsayed RA, Tomich CE, Hanks CT, Fear D, Meyrowitz S. Metastatic tumors in the jaws: a retrospective study of 114 cases. *J Am Dent Assoc.* 2006;137:1667–72. <https://doi.org/10.14219/jada.archive.2006.0112>.
- Barnes L. Metastases to the head and neck: an overview. *Head Neck Pathol.* 2009;3:217–24. <https://doi.org/10.1007/s12105-009-0123-4>.
- Andabak Rogulj A, Tomasovic Loncaric C, Muller D, Blivajns I, Andabak M, Vucicevic Boras V, Sekerija M. Solid malignant metastases in the jaw bones. *Br J Oral Maxillofac Surg.* 2018;56:705–8. <https://doi.org/10.1016/j.bjoms.2018.07.013>.

13. Thiele OC, Freier K, Bacon C, Flechtenmacher C, Scherfler S, Seeberger R. Craniofacial metastases: a 20-year survey. *J Cranio-Maxillofac Surg.* 2011;39:135–7. <https://doi.org/10.1016/j.jcms.2010.10.009>.
14. Shen ML, Kang J, Wen YL, Ying WM, Yi J, Hua CG, Tang XF, Wen YM. Metastatic tumors to the oral and maxillofacial region: a retrospective study of 19 cases in west china and review of the Chinese and English literature. *J Oral Maxillofac Surg.* 2009;67:718–37. <https://doi.org/10.1016/j.joms.2008.06.032>.
15. van der Waal RIF, Buter J, van der Waal I. Oral metastases: report of 24 cases. *Br J Oral Maxillofac Surg.* 2003;41:3–6. [https://doi.org/10.1016/S0266-4356\(02\)00301-7](https://doi.org/10.1016/S0266-4356(02)00301-7).
16. Jham BC, Salama AR, McClure SA, Ord RA. Metastatic tumors to the oral cavity: a clinical study of 18 cases. *Head Neck Pathol.* 2011;5:355–8. <https://doi.org/10.1007/s12105-011-0286-7>.
17. Murillo J, Bagan JV, Hens E, Diaz JM, Leopoldo M. Tumors metastasizing to the oral cavity: A study of 16 cases. *J Oral Maxillofac Surg.* 2013;71:1545–51. <https://doi.org/10.1016/j.joms.2013.03.017>.
18. Lossos A, Siegal T. Numb chin syndrome in cancer patients: etiology, response to treatment, and prognostic significance. *Neurology.* 1992;42:1181–4. <https://doi.org/10.1212/wnl.42.6.1181>.
19. Nortjé CJ, Wood RE, Padayachee A. Soft tissue proliferation in a non-healing extraction site. a sign of metastatic malignancy. *Dentomaxillofac Radiol.* 1987;16:109–11. <https://doi.org/10.1259/dmfr.25.5.9161185>.
20. Friedrich RE, Abadi M. Distant metastases and malignant cellular neoplasms encountered in the oral and maxillofacial region: analysis of 92 patients treated at a single institution. *Anticancer Res.* 2010;30:1843–8.
21. Neyaz Z, Gadodia A, Gamanagatti S, Mukhopadhyay S. Radiographical approach to jaw lesions. *Singap Med J.* 2008;49:165–77.
22. Yoo J, Henderson S, Walker-Dilks C. Evidence-based guideline recommendations on the use of positron emission tomography imaging in head and neck cancer. *Clin Oncol.* 2013;25:e33–66. <https://doi.org/10.1016/j.clon.2012.08.007>.
23. Clausen F, Poulsen H. Metastatic carcinoma to the Jaws. *Acta Pathol Microbiol Scand.* 1963;57:361–74. <https://doi.org/10.1111/j.1699-0463.1963.tb05105.x>.

Publisher's Note Springer Nature remains neutral with regard to jurisdictional claims in published maps and institutional affiliations.