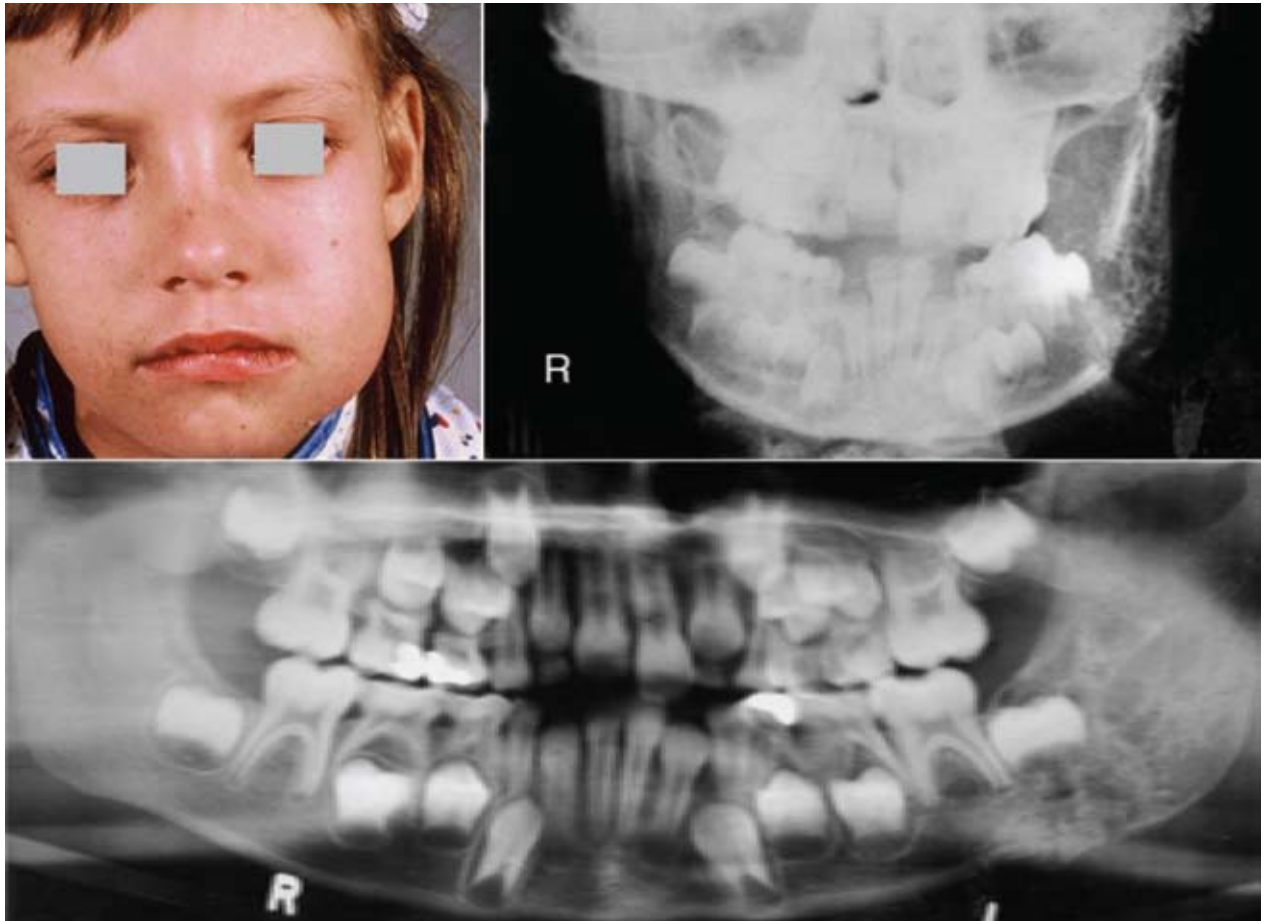


Maxillo-facial radiology case 108

SADJ March 2013, Vol 68 no 2 p78

CJ Nortjé

This 8-year-old female came to her paediatrician with an 18-day history of facial swelling. A biopsy was performed at that time, and was interpreted as indicating Burkitt's lymphoma. Findings from blood studies and chest radiographs were normal. Clinical examination revealed an 8 x 9 cm hard tumour attached to the left side of the mandible. Enlarged firm submandibular lymph nodes were also present. What is your diagnosis?



INTERPRETATION

The pantomograph and the posterior-anterior view of the mandible show an expansile, permeative, destructive lesion extending from the region of the mandibular left molar tooth to the condylar neck. The lesion is poorly demarcated and uncorticated at its periphery. The internal structure consists of multiple discrete polymorphous radiolucent areas, ranging in size from 1mm to several millimetres. These zones are, in turn, are surrounded by thin sclerotic margins. The cortex of the follicle of the left second molar tooth (37) is destroyed, and the tooth is displaced anteriorly and superiorly. Cortical destruction is evident at the inferior and posterior borders of the left mandible and in the cortex of mandibular canal. The periosteal reactions consist of sun-ray type spicules emanating from the inferior border of the body of the mandible, suggestive of Codman's triangle at the anterior edge of this site. Further testing was performed. Technetium bone scans revealed that the osseous changes were limited to the mandible. Bone marrow aspirate, blood count, skeletal survey, cerebrospinal fluid, abdominal

ultrasound and liver function studies were all normal. Screening for Epstein-Barr virus was negative. A second biopsy was performed and the final histological diagnosis was Ewing's sarcoma. The pathogenesis of Ewing's sarcoma is unknown. Any bone may be involved, but tubular bones are more likely to be affected than flat bones. The lesion arises in the medullary cavity and may spread to involve all internal aspects of the bone. It is rarer than osteogenic sarcoma and chondrosarcoma and is especially rare in the facial bones and jaws. When it does affect a jaw bone, it is more likely to be in the mandible, especially the ramus. The peak age incidence is in the second decade of life, with 90% of patients between the ages of five and 30 years. Ewing's sarcoma is twice as prevalent in males as in females and is said to be rare in negroids. Clinically the tumors are heralded by local bone pain, fever, a sense of ill health, localised swelling and deformity. In long bones pathological fractures occur. In the jaw, facial neuralgia, swelling and localised destruction may be present. Loosened teeth and mucosal ulcers may also occur. Cervical lymphadenopathy may be noted.

CJ Nortjé: BChD, PhD, ABOMR, DSc. Faculty of Dentistry, University of the Western Cape. E-mail: cnortje@uwc.ac.za

Reference

1. Farman AG, Nortje CJ & Wood R E: Oral and Maxillofacial Imaging, 1st Ed, Mosby. St. Louis, Missouri 1993, pp295-297.