

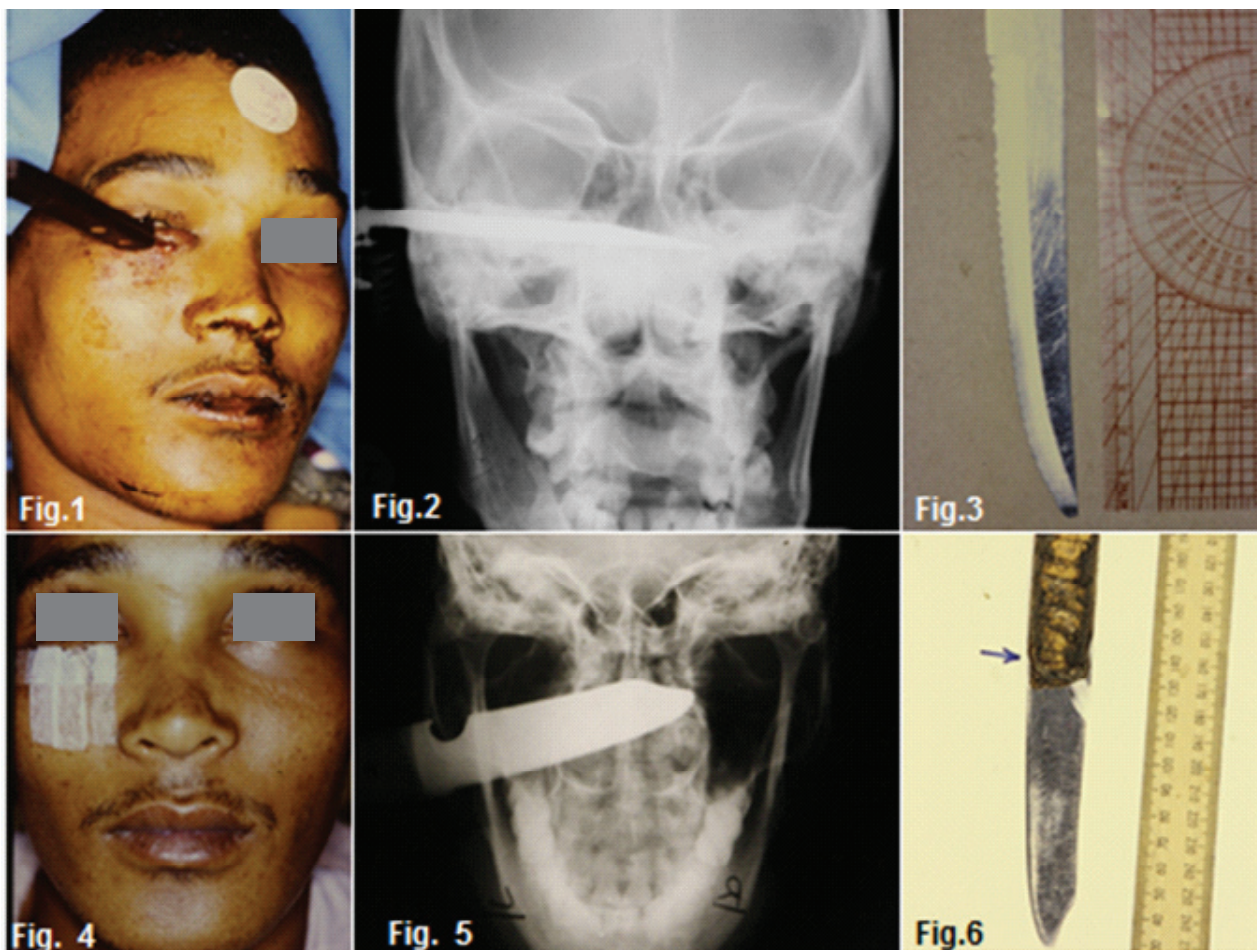
Maxillo-facial radiology case 138

SADJ March 2016, Vol 71 no 2 p81

CJ Nortjé

Below are two cases of intentional knife wounds of the maxillofacial region, examples of trauma cases which do present fairly often at the Hospital for treatment. Clinical and radiological examination of Case 1 (Figures 1, 2, 3 and 4) revealed that the knife had passed through the right lateral wall of the orbit. The point of the knife was palpable subcutaneously near the left nasal bridge. There was proptosis and ptosis of the right eye. The knife blade was

withdrawn along the same path as it had been inserted, with the patient under general anaesthesia. Case 2 (Figures 5 and 6) presented with a knife protruding from the patient's eye socket. Radiographic examination revealed the path and the size of the knife. The knife was removed surgically in the same manner as the previous case. These deliberately inflicted injuries to the maxillofacial region are grouped into a syndrome...under what name?



DISCUSSION

The term Jael's Syndrome is an oblique Biblical reference to the murder of Sisera by Jael in Judges IV, 21 "Sisera was so tired that he fell sound asleep. Then Jael took a hammer and a tent-peg, went up to him quietly, and killed him by driving the peg through the side of his head into the ground." The first report of Jael's syndrome is attributed to Jefferson (1968) who described a severe, accidental craniofacial injury to a 16 year old boy who was impaled on a tent peg. The term was further defined by McKechnie (1986) who reported a case in which a fence post was driven through the temple of a 21 year old accident victim.

Other grotesque injuries of this type have been previously reported. According to Harris *et al* (1988) the term Jael's syndrome is an intentional craniofacial stab injury. To be sure, these cases do not represent tent peg homicides of a somnolent victim as in tale of Jael and Sisera. Despite this, they can be defined as Jael's syndromes since deliberate penetrating wounds of the face resulted from an assault. What is surprising is the complete absence of serious signs and symptoms in these two patients.

Reference

1. Jefferson, A.A (1968) in McKechnie, J: A severe craniofacial impalement injury (Jael's syndrome). Brit. J. Oral Maxillofacial. Surg. 24 (1986) 258.
2. Harris A M P, Wood RE, Nortje CJ and Grotepass FG: Deliberately inflicted penetrating Injuries of the maxillofacial region (Jael's syndrome). J Cranio.Max. Fac. Surg. 16 (1988) 60-3..