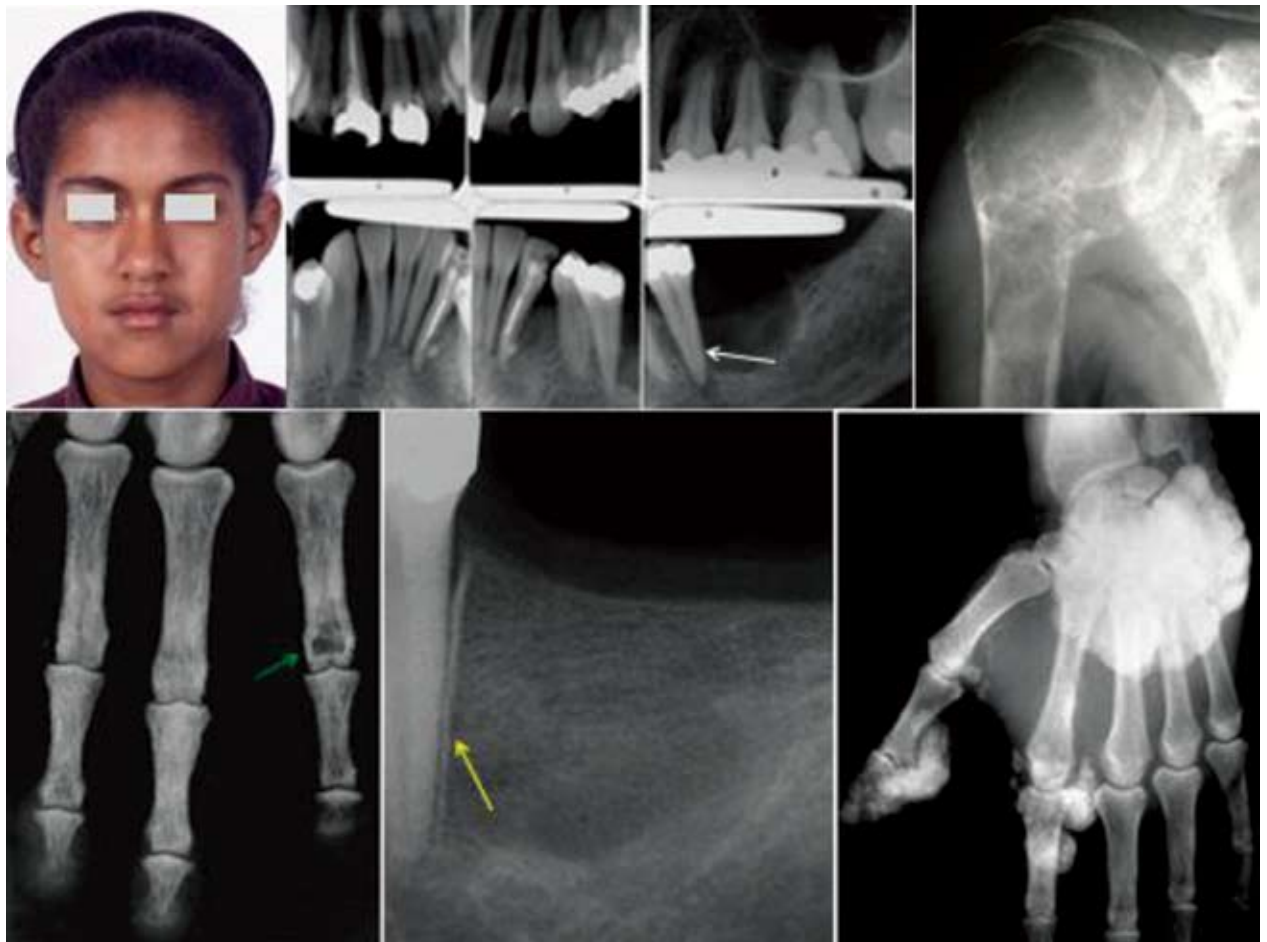


Maxillo-facial radiology case 115

SADJ October 2013, Vol 68 no 9 p424 - p425

CJ Nortjé

An 18-year-old female referred by her dental practitioner, with the main complaint that the lower left second premolar tooth (35), is mobile. She also complains of gastrointestinal problems, nausea, bone pain and muscle weakness. Whilst the intraoral radiographs were being taken, the patient had a problem trying to hold the intraoral apparatus with her right arm, which according to her was due to the fact that a "malignant tumour" was removed from the head of the right humerus (upper shoulder radiograph) 10 months previously. According to a report from her general practitioner, a frozen section was done at that time, which was diagnosed histologically to be a giant cell tumour. A resection was done and the head of the humerus was replaced with a prosthesis.



INTERPRETATION

After clinical evaluation in the Oral Surgery Department the patient was referred for blood tests to determine the serum calcium status. The results indicated a calcium value of 13.7mg/dl (normal 8.5-10.5 mg/dl). The patient was referred to the Department of General Surgery who after clinical examination identified a tumour of the lower left parathyroid gland which was removed. A biopsy of the radiolucency

distal to the 35 appeared to indicate the presence of a brown tumour. Microscopic evaluation of the parathyroid tumour confirmed the presence of an adenoma and a final diagnosis of primary hyperparathyroidism was made. The pantomograph and intraoral radiographs showed generalised rarefaction of the jawbones, loss of lamina dura around the roots of a number of teeth especially the 35 (white arrow) and a well demarcated radiolucency distal to the 35. The shoulder radiograph shows a multilocular cystic radiolucency with coarse trabeculation on the medial surface representing a brown tumor. The lower left radiograph of the same patient

CJ Nortjé: BChD, PhD, ABOMR, DSc. Faculty of Dentistry, University of the Western Cape. E-mail: cnortje@uwc.ac.za

shows patchy mineralisation of the digits and possible brown tumour (green arrow). The lower intra oral radiograph twelve months later shows complete remodeling of the brown tumour and presence of the lamina dura (yellow arrow). The lower hand and wrist radiograph of another patient with primary hyperparathyroidism shows metastatic calcifications in the muscles and subcutaneous tissues. Hyperparathyroidism occurs in **three** clinical forms: primary, secondary and tertiary. In all instances, the disease is characterised by an increase in Parathyroid Hormone (PTH) levels and mobilisation of calcium from bone. The disease appears more commonly in women with a peak incidence between the ages of 40 and 50 years. The most common sequel of the disease is renal calcification. The stones ultimately may cause renal damage and uremia. The bony changes in hyperparathyroidism are identical, whether the cause is primary, secondary or tertiary. The classic radiological features of hyperparathyroidism are as follows: sub periosteal bone resorption of the mid phalanges, generalised demineralisation, localised lytic bone lesions, known as brown tumours, and metastatic calcification of soft tissues. Edeiken (1981) asserted that the earliest changes in hyperparathyroidism occur in the hands, calvaria, and alveolar bone of the jaws. Resorption of the lamina dura is the first sign of de-ossification in the jaws. In 220 patients studied by Rosenberg and Guralnick, the lamina dura was absent in 40% of the cases. When the lam-

ina dura was missing, 62% of cases exhibited classic bone disease, 27% had demineralisation only and 11% showed no apparent disease. Thus the absence of the lamina dura is a good indicator of the degree of skeletal bone involvement. Brown tumours are histologically identical to central giant cell granuloma and the surgical specimen appears brown. A histological diagnosis of central giant cell granuloma always must be followed by a workup for hyperparathyroidism, especially when the following conditions are evident; (1) the lesion is posterior to the first molars in the body of the mandible or anywhere in the maxilla, (2) the lesion is in the ramus, (3) several lesions are present, or (4) there are multiple recurrences. Brown tumours tend to be monocystic, without marginal scalloping, although internal septa may rarely be seen. The borders may be poorly defined, and there may appear a zone of reactive bone outlining the lesion. In addition, some may resemble cystic lesions.

Declaration: No conflict of interest declared.

References

1. Edeiken J: Roentgen Diagnosis of Diseases of Bone. Baltimore, Williams & Wilkins, 1981.
2. Rosenberg EH, Guralnick WC: Hyperparathyroidism: a review of 220 proved cases, with special emphasis on findings in the jaws. Oral Surg Oral Pathol 15: 84, 1962.