

Use of the passive lower lingual arch in the management of anterior mandibular crowding in the mixed dentition

SADJ April 2013, Vol 68 no 3 p114 - p119

APG Hudson,¹ AMP Harris,² N Mohamed,³ J Joubert.⁴

ABSTRACT

Leeway space preservation in the mixed dentition is a well-documented method of space management. In the mandibular arch it may be saved for utilisation in the correction of minor anterior crowding by the placement of a passive lower lingual arch (LLA) during the transition from the mixed dentition to the permanent dentition.

Keywords: Passive lower lingual arch, leeway space, anterior mandibular crowding, non-extraction treatment.

INTRODUCTION

Mandibular incisor crowding of approximately one to two mm is not uncommon during the early mixed dentition stage. Provided that the posterior permanent teeth erupt in a favourable sequence, this incisor liability is viewed as normal and usually resolves spontaneously.¹ Should the incisor crowding be greater than two mm, however, it is unlikely that it will self-correct, may well become a feature of the permanent dentition¹ and in some cases, can actually increase.² Mandibular anterior crowding is one of the most common problems requiring orthodontic intervention.³

NORMAL DEVELOPMENT

During the normal transition from the primary to the permanent dentition, spaces between some teeth occur.¹ These

1. **APG Hudson:** BChD (Stell), HonsBSc (Med Sci) (Stell), MSc (Dent) (UWC). Senior Lecturer, Department of Orthodontics, Faculty of Dentistry, University of the Western Cape.
2. **AMP Harris:** BChD (Stell), HonsBSc (Med Sci) (Stell), Dip/TerEduc (Unisa), MChD Orthodontics (Stell), FFD(SA) Ortho, PhD (UWC). Professor and Head of Department of Orthodontics, Faculty of Dentistry, University of the Western Cape.
3. **N Mohamed:** BChD (Stell), BSc Hons (Paed Dent) (Stell), MSc (Paed Dent), (Stell). Senior Lecturer, Department of Paediatric Dentistry, Faculty of Dentistry, University of the Western Cape.
4. **J Joubert:** BChD (UWC), PDD (Interceptive Orthodontics). Private practice.

Corresponding author

APG Hudson:

Faculty of Dentistry; Private Bag X1; Tygerberg; 7505; Tel: 021 937 3104; Fax: 021 931 2287. Email: apghudson@uwc.ac.za

ACRONYMS

LLA: Lower Lingual Arch

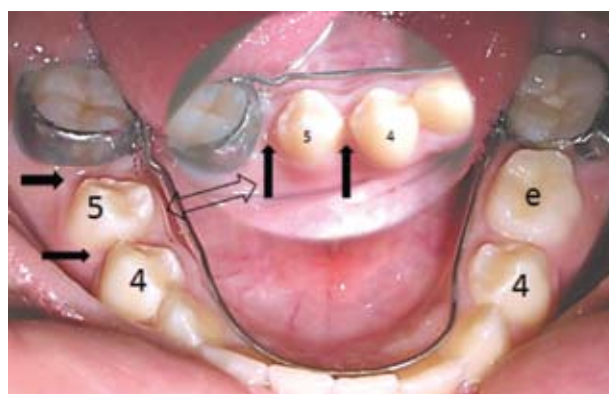


Figure 1: The tooth 85 has exfoliated and the arrows indicate the leeway space that has been maintained by the passive lingual arch.

spaces (the primary and primate spaces as well as the leeway space) play a role in the development of the permanent dentition. As the three primary buccal segment teeth (i.e. c, d, and e) occupy more space in the arch than will do their permanent successors, this additional space ("leeway space") may be sufficient to allow for the correct positioning and alignment of the permanent teeth (Figure 1). The size of the leeway space varies from individual to individual. On average, it has been found to range from 1.5 to 2.5mm per mandibular buccal quadrant while in the maxilla it ranges from 0.8 to 1.5mm per buccal quadrant.^{4, 5, 6, 7, 8} The leeway space eventually disappears spontaneously due to mesial drifting of the posterior permanent teeth when the last of the deciduous teeth exfoliate, resulting in a loss of arch length and a change in the molar relationship.⁵ Approximately four mm of arch perimeter may be lost during this process.⁹ It has been shown in mixed dentition cases with anterior mandibular crowding of up to five mm, that conserving the leeway space by preventing the mesial drift often provides enough space to resolve the incisor crowding.^{2, 10, 11, 12, 13}

Arch length preservation may be achieved by the placement of a passive lower lingual arch⁴ (Figures 1 & 2). Prior



LISTERINE ZERO™

A breakthrough in delivering efficacy
without alcohol

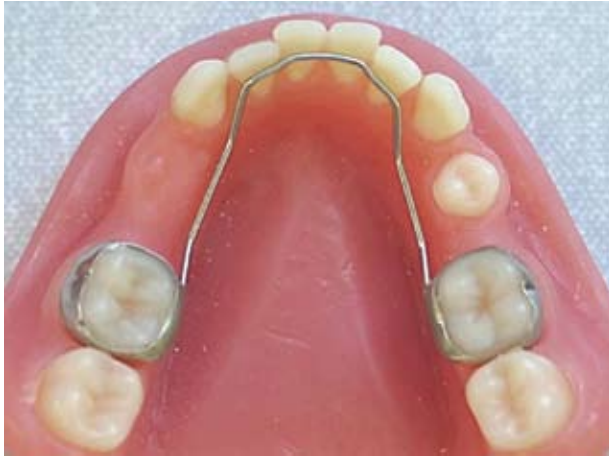

Figure 2: The passive lingual arch is designed to rest on the cingula of the incisors only. The archwire between the incisors and molars must be out of the bite and should not prevent the premolars and permanent canines from erupting.

to treatment, the clinician should take note of the intermaxillary first molar relationships. The maintenance of mandibular arch length may lead to the development of an unfavourable molar relationship if the maxillary molar is allowed to follow normal development and drift mesially into the upper arch leeway space, whilst any drift of the lower molars is prevented.^{5, 14} The upper molar may therefore have to be distalised to re-establish a sound molar occlusion.

The purpose of this paper is to explore the utilisation of leeway space in the mixed dentition using a passive lower lingual arch (LLA), as a means to relieve anterior crowding in the mandibular arch. The rationale behind this interception is twofold, namely to:

- facilitate the accommodation of all the permanent teeth in the lower arch anterior to the first permanent molar as part of the orthodontic treatment programme;
- possibly completely eliminate the need for further orthodontic treatment.

APPLIANCE DESIGN

The LLA consists of closely fitting stainless steel bands on teeth 36 and 46, joined by a 0.9mm stainless steel arch wire¹⁵ which rests passively on the cingula of the lower incisors (Figure 2). In the canine and premolar region, the arch wire should be positioned apical to the marginal gingiva of the primary teeth and closely adapted to the soft tissue.⁴ The arch wire is therefore protected from the forces of occlusion which can break or distort the appliance. Distortion of the appliance may result in an undue increase or decrease of the arch length.²

THE INTERCEPTIVE APPROACH TO MINOR MANDIBULAR ANTERIOR CROWDING

When considering overall accommodation in the arch, leeway space may be utilised to enable proper lower incisor alignment.^{4, 13} Brennan and Gianelly² placed passive lingual arches in 107 patients at the mixed dentition phase and followed them through to the stage when second premolars had erupted. The study found that the average amount of incisor crowding that was resolved was five mms. "In 65 of

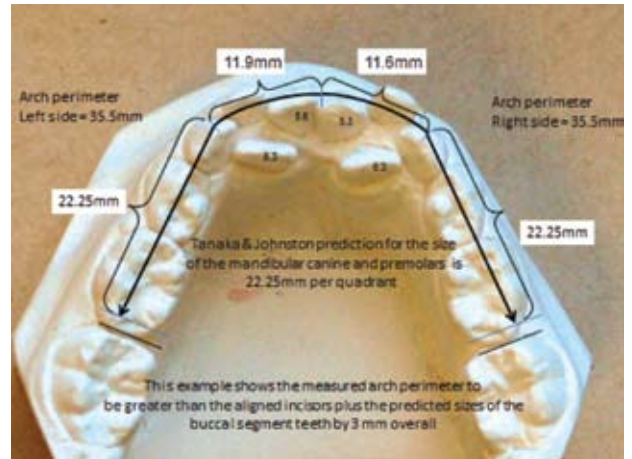


Figure 3: In this example of a Mixed Dentition Space Analysis, the Tanaka and Johnston prediction formulae¹⁶ have been used. The measurements show that after incisor alignment, there will be three mms of excess space into which the posterior teeth may drift.

the 107 patients (61%) there was ample space to resolve incisor crowding completely". Fourteen of the cases however, recorded a final accommodation problem of greater than two mms. Brennan and Gianelly² conclude that arch length preservation in the mixed dentition provides space to correct crowding in the majority of patients.

In all instances when a passive lingual arch is contemplated a Mixed Dentition Space Analysis is indicated. Firstly the mesio-distal dimensions of the lower incisors are measured and a pair of calipers is used to determine that point which would locate the distal surface of the lower lateral incisor were the incisors to be correctly aligned along the ideal arch perimeter. The distance along the arch from that point to the mesial contact point of the lower first permanent molar provides the measure of how much space will be available in that buccal segment, assuming that mesial drift of the lower molar is prevented by a lingual arch. Now it is necessary to predict the sizes of the succedaneous teeth which are due to erupt into the space available.

There are numerous methods of predicting the size of these unerupted teeth of the buccal segments in the calculations of leeway space. A radiologically based calculation as described by Nance⁴ in 1947 allows for accurate assessment of the sizes of the individual unerupted permanent teeth. Tables or formulae are now more commonly used to predict the combined size of the permanent canines and premolars on one side of the arch.^{7,16,17} Prediction tables which incorporate magnification correction factors may also be referred to.^{18,19} The predicted space required to accommodate the lower premolars and canine is now compared with the space available in that segment to provide an assessment of any potential accommodation problem (Figure 3).

APPLICATION AND USE OF THE LOWER INTER MALAR RETAINER – LLA

Mandibular incisor crowding is significantly linked to a diminished transverse dimension of the mandibular arch.²⁰ Early extraction of the primary canines often appears an attractive option.²¹ However, a natural widening of the arch is associ-



NEW LISTERINE ZERO™

A breakthrough in delivering efficacy without alcohol

ated with normal canine eruption and root resorption of the primary canines.¹ This arch widening effect would be lost by the extraction of the deciduous canines, an unfavourable outcome. An alternative is the extraction of the first primary molar which would provide some space but would still allow for the widening effect. Mildly crowded lower incisors tend to self-align against the lingual arch, taking up space provided by the early extraction of the primary first molars. In these cases, the permanent mandibular canines are more likely to move into a favourable position, provided that they are erupting ahead of the first premolars. This early alignment is regarded as important in the long term stability of the lower anterior segment of the arch.²²

The spontaneous early loss of one or both the mandibular primary canines is an early warning sign of space shortage.¹ This is a problem which can result from pressure of the crown of the erupting mandibular permanent lateral incisors on the root of the primary canine resulting in resorption of the root, precipitating early exfoliation of the canine (at the dental age of 7 years) prior to the eruption of the maxillary lateral incisors (at the dental age of 8 years).²³ Under the influence of the mentalis muscle, the lower incisors then tip distally and lingually into the space previously occupied by the primary canine.²⁰ In cases where there has been unilateral spontaneous early loss of the primary canine, the incisors on the affected side tip lingually as a result of the loss of interproximal contact and the effect of the mentalis muscle, causing the bite to deepen and the midline to shift.¹ Extraction of the antimere is now indicated and should be effected as soon as possible, followed by placement of a passive lingual arch.

Bilateral spontaneous early loss of the primary canines leads to a bilateral loss of arch perimeter and deepening of the bite without a midline shift.¹ In this situation, incisor crowding is

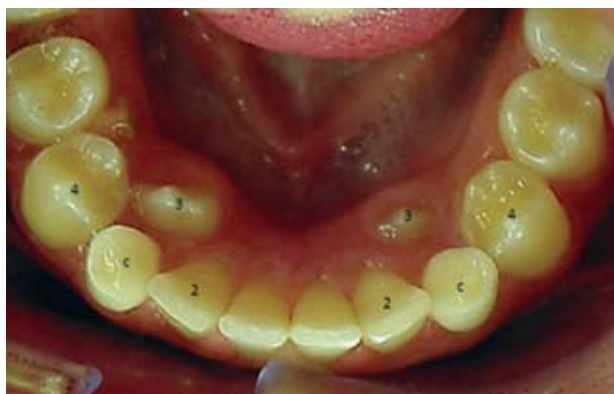

Figure 4: An unfavourable sequence of eruption resulting in the canines being blocked out.

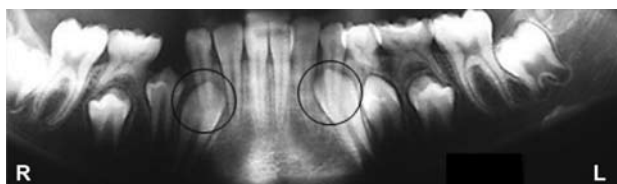

Figure 5: An unfavourable sequence of eruption on the right side due to the early loss of the d and the atypical delayed resorption of the root of the 83. The left side also shows atypical lack of resorption of the root of the 73 which will affect the eruption of the 33 and result in an unfavourable sequence of eruption.

often resolved by the action of the muscles of the lip and tongue which forces the lateral incisor distally into the space of the primary canine, even as it collapses lingually, thus shifting the space shortage to the buccal segments.²¹ A passive lingual arch will be indicated, preferably as an early preventive measure.

The sequence of eruption of the permanent canine and first premolar is critical to anterior alignment.²⁴ The most favourable sequence of eruption for mandibular permanent teeth is 6, 1, 2, 3, 4, 5, 7, 8.²² Should the first premolar erupt prior to the canine, crowding will likely result as the canine is blocked out, forcing it to erupt either labially or lingually (Figure 4).

A pantomogram can be used to predict the sequence of eruption.²⁵ Anomalous root resorption of the primary canines and early spontaneous loss of the first primary molar are common causes for an unfavourable sequence of eruption of the permanent canine and first premolar²⁵ (Figure 5). If the permanent canine and the first premolar are erupting in an unfavourable sequence, a lingual arch may be timeously (immediately) placed so as to maintain the arch length and utilise the leeway space, thereby facilitating the alignment of the incisors, canines and first premolars.

THE SUCCESS RATE OF LEEWAY SPACE UTILISATION

This has been reported on in numerous clinical trials.^{2, 12, 13} In the Brennan and Gianelly² study, 87% of 107 patients displayed less than two mm of crowding after passive lingual arch appliances had been placed in the mixed dentition.

Arnold (as cited by Brennan and Gianelly)² reported that where there was an average of 4.5mm of incisor crowding, sufficient space was present after LLA therapy to correct the crowding in 72% of cases. The relationship between spontaneous early loss of the primary canines and crowding is evidenced by the finding that 94% of similar patients developed crowding when left untreated. In 39% of cases, however, crowding could be resolved if leeway space was utilised, provided the lingual arch was placed as soon as possible after tooth loss.²

In the long term, 76% of patients successfully treated with a passive lingual arch appliance may be considered to have a stable dentition.¹¹ This form of treatment is believed to produce more stable results than those achieved by arch expansion.^{2, 11, 26}

COMPLICATIONS AND EFFECTS OF THE LINGUAL ARCH APPLIANCE

The following may be regarded as potential complications associated with the use of a lower lingual arch:

- the development of caries;
- habitual fiddling by the tongue;
- increased risk of tooth impaction distal to the 6s;
- transverse restriction of the mandibular arch.

There is an increased risk of caries associated with the placement of molar bands. In the authors' experience it is



LISTERINE ZERO
A breakthrough in delivering efficacy
without alcohol

beneficial to use a fluoride releasing band cement. Removing and recementing the bands every six months to eliminate the potential for any caries developing under bands due to partial cement failure is also recommended.

The close approximation of the arch wire to the incisors and soft tissues is important. Poor approximation may irritate the tongue, encouraging the patient to fiddle with the wire which in turn may distort or dislodge the arch.

Studies have shown that incisor proclination and molar retroclination may be associated with a fitted lingual arch.^{13,27} Second molar eruption problems occur in up to 2.3% of the general population.²⁸ Rubin *et al*²⁹ found that 4.7% of patients developed eruption problems of second permanent molars after treatment using passive lower lingual arches. Second molars that display an inter-molar angulation of 24° or more to the first molar are more likely to be impacted (Figure 6). In a study of 200 cases²⁸ where passive lingual arches were fitted, results indicate that 14.5% of these patients displayed at least one second molar impaction. Of the 400 second molars in the study, only 8.5% were impacted. Sonis and Ackerman²⁸ found no significant association between inter-molar spacing (Figure 6) and impaction, or between third molar presence and second molar impaction. Third molar impaction in non-extraction treatment protocols occur more commonly than in cases where extractions have been performed. Kim *et al*³⁰ reported a 40% mandibular third molar impaction rate in non-extraction cases as opposed to 22% in extraction cases.

The results of a study by Rebelato *et al*⁹ showed no restriction of the transverse dimension in a group of patients treated with a lingual arch when compared with a control group. It is however the authors' experience that in isolated cases the mandibular molars may tilt lingually. In these cases, the LLA may be adjusted in the transverse dimension during a recementation visit. The intercanine distance is thought to increase because the canine drifts distally and buccally into the leeway space.^{2, 15}

The LLA restricts vertical eruption of the mandibular molars.^{26,31} If employed early in a patient exhibiting excessive vertical growth tendencies, it may have this additional beneficial effect.³¹

GUIDELINES FOR SUCCESSFUL CASE SELECTION AND TREATMENT

- The patient should be a Class I dentally and skeletally. In Class II and III cases, the use of the LLA should form part of a comprehensive orthodontic treatment plan.
- The patient's oral hygiene should be impeccable.
- Late mixed dentition treatment is appropriate. The mandibular arch must be intact i.e. no tooth loss or improperly contoured interproximal restorations. In the case of spontaneous loss of the primary canines, the LLA should be placed within one month of the primary tooth exfoliating.
- The amount of anterior crowding must be less than five mm.

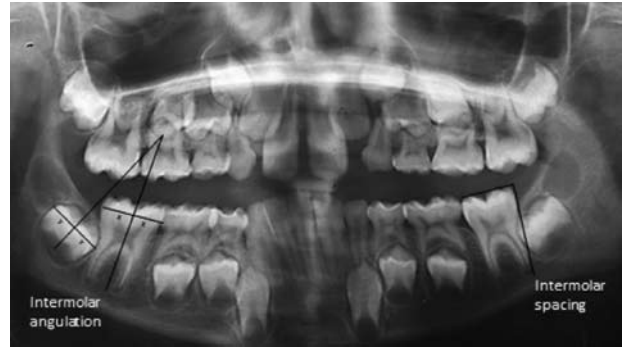


Figure 6: An unfavourable intermolar angle of 22° on the right side, with an intermolar spacing of minus two mm on the left side.

- The patient should have a pantomograph taken in order that the developing dentition may be assessed.
- Prior to proceeding with the treatment, the second molars should be carefully assessed for impaction potential. An intermolar angle of 200 or more should be regarded as a warning sign and other forms of treatment should be investigated and / or considered.
- The co-operation of the patient after the appliance has been fitted is very important.
- The risks associated with 'fiddling' should be made clear to both the patient and parents. Appliance displacement as a result of 'fiddling' may be countered by bonding a composite button on an incisor just superior to the arch wire.⁴ The importance of regular follow up appointments, at least once every three months needs to be stressed, in order to check the appliance for signs of distortion as well as for regular six monthly removal and recementation of the LLA.
- The appliance is removed once the premolars and canines have fully erupted.

CONCLUSIONS

The general practitioner is well positioned to identify patients suitable for this type of treatment. Liaison between the dentist, patient and orthodontist is particularly important in borderline cases, so as to pre-empt the potentially embarrassing situation of still having to do extractions after leeway space utilisation has been attempted. The parents and the child need to fully understand the rationale of the proposed treatment. The chances of success should be thoroughly explained and the importance of treatment timing must be understood by parents and the patient as well as the potential for complications. Any other treatment that may have to follow (i.e. maxillary treatment) should be discussed with the parents during the planning stages. The potential for a second phase of treatment for the active alignment of the incisors also should be discussed, as the expectation of self-alignment of the incisors may be unrealistic in all cases.

The LLA is an effective appliance for preserving arch length and its effect is generally accepted. Utilising the leeway space in order to resolve mandibular incisor crowding has gained popularity and may have contributed to the steady decline of full orthodontic extraction cases in recent decades.



LISTERINE ZERO™

A breakthrough in delivering efficacy
without alcohol

Declaration: No conflict of interest declared.

References

1. Nanda SK. Events in the lifecycle of each permanent tooth. In: The Developmental Basis of Occlusion and Malocclusion. Chicago: Quintessence Publishing, 1983: 81-158.
2. Brennan MM, Gianelly AA. The use of the lingual arch in the mixed dentition to resolve incisor crowding. Am J Orthod Dentofac Orthop 2000; 117: 81-5.
3. Gianelly AA. Crowding: Timing of treatment. Angle Orthod 1994; 64: 415-8.
4. Nance HN. The limitations of orthodontic treatment. 1. Mixed dentition diagnosis and treatment. Am J Orthod Oral Surg 1947; 33: 177-223.
5. Moorrees CFA, Chada JM. Available space for incisors during dental development: a growth study based on physiologic age. Angle Orthod 1965; 35: 12-22.
6. Graber TM. Preventive orthodontics. Maintenance of a normal occlusion. In: Orthodontics, Principles and Practice. 2nd ed. Philadelphia: WB Saunders, 1966: 630-70.
7. Moyers RE. Analysis of dentition and occlusion. In: Handbook of Orthodontics. 4th ed. Chicago: Year Book Medical Publishers, 1988:221-45.
8. Gordon PH. Craniofacial growth and development. In: Paediatric Dentistry. 2nd ed. New York: Oxford University Press, 2001: 3-15.
9. Rebellato J, Lindhauer SJ, Rubenstein LK, Isaacson RJ, Davidovitch M, Vroom K. Lower arch perimeter preservation using the lingual arch. Am J Orthod Dentofac Orthop 1997; 112: 449-56.
10. Gianelly AA. Treatment of crowding in the mixed dentition. Am J Orthod Dentofac Orthop 2002; 121: 569-71.
11. Dugoni S, Lee JS, Valera J, Dugoni A. Early mixed dentition treatment: postretention evaluation of stability and relapse. Angle Orthod 1995; 65: 311-9.
12. De Baets J, Chiarini M. The pseudo-class I: A newly defined type of malocclusion. JCO 1995; 29: 73-88.
13. Viglianisi A. Effects of lingual arch used as a space maintainer on mandibular arch dimension: A systematic review. Am J Orthod Dentofac Orthop 2010; 138: 382.e1-e4.
14. Patti A, Perrier D'Arc G. Appliances. In: Clinical Success in Early Orthodontic Treatment. Paris: Quintessence Books, 2005: 101-18.
15. Owais AI, Rousan ME, Badran SA, Abu-Alhaja ES. Effectiveness of a lower lingual arch as a space holding device. Eur J Orthod 2011; 33: 37-42.
16. Tanaka MM, Johnston LE. The prediction of the size of unerupted canines and premolars in a contemporary orthodontic population. J. Am. Dent Assoc 1974; 88: 798-801.
17. Khan MI. Tooth width predictions in a sample of Black South Africans. Masters dissertation, University of Limpopo, 2006
18. Hixon EH, Oldfather RE. Estimation of the sizes of unerupted cuspid and bicuspid teeth. Angle Orthod 1958; 28: 236-40.
19. Staley RN, Kerber PE. A revision of the Hixon and Oldfather mixed dentition prediction method. Am J Orthod Dentofac Orthop 1980; 78: 226-302.
20. Sayin M, Türkkahraman H. Factors contributing to mandibular anterior crowding in the early mixed dentition. Angle Orthod 2004; 74: 754-8.
21. Sayin M, Türkkahraman H. Effects of lower primary canine extraction on the mandibular dentition. Angle Orthod 2006; 76: 31-5.
22. P Dugoni S. The three W's of early treatment: Who, When, Why. PCSO bulletin summaries. 2007: 24-5.
23. Proffit WR. The later stages of development. In: Contemporary Orthodontics. St Louis: CV Mosby, 1986: 63-94.
24. Burdi AR, Moyers RE. Development of the dentition and the occlusion. In: Moyers RE. Handbook of Orthodontics, 4th ed. Chicago: Year Book Medical Publishers, 1988: 99-146.
25. Hudson APG, Harris AMP, Mohamed N. The mixed dentition pantomogram: A valuable dental development assessment tool for the dentist. SADJ 2009; 64: 480-3.
26. Little RM. Stability and relapse: Early treatment of arch length deficiency. Am J Orthod Dentofac Orthop 2002; 121: 578-81.
27. Singer J. The effect of the passive lingual arch on the lower denture. Angle Orthod 1974; 44: 146-55.
28. Sonis A, Ackerman M. E-space preservation. Is there a relationship to mandibular second molar impaction? Angle Orthod 2011; 81: 1045-9.
29. Rubin RL, Bacetti T, Mc Namara JA. Mandibular second molar eruption difficulties related to the maintenance of arch perimeter in the mixed dentition. Am J Orthod Dentofac Orthop 2012; 141: 146-52.
30. Kim T-W, Artun J, Behbehani F, Artese F. Prevalence of third molar impaction in orthodontic patients treated non-extraction and with extraction of four premolars. Am J Orthod Dentofac Orthop 2003; 123: 138-45.
31. Villalobos FJ, Sinha PK, Nanda RS. Longitudinal assessment of vertical and sagittal control in the mandibular arch by the mandibular fixed lingual arch. Am J Orthod Dentofac Orthop

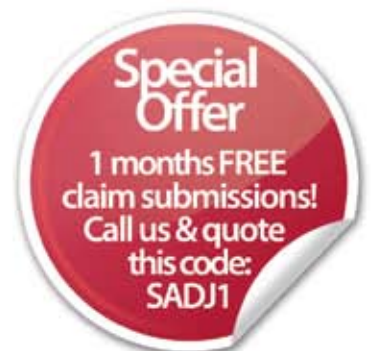

The right tool for the job is often the one you don't see.

Every month, MediSwitch quietly validates and submits over 8 million claims - that's 29 million transaction lines per month in South Africa alone.

MediSwitch delivers electronic claims to more medical schemes than any other switching company. As the undisputed pioneer of cost effective online claims delivery in South Africa, MediSwitch is trusted by more medical professionals than any other switching company.

So, if you want your practice as equipped to do the job as you are, join MediSwitch and get the right tools for the job.



medi|switch
the trusted claim in healthcare

0800 111 703 | www.mediswitch.co.za
sales@mediswitch.co.za